



Scientific Committee on Emerging and Newly Identified Health Risks

SCENIHR

**Preliminary opinion on
The safety of Metal-on-Metal joint replacements
with a particular focus on hip implants**

SCENIHR approved this opinion for public consultation by written procedure on 24 February
2014

About the Scientific Committees

Three independent non-food Scientific Committees provide the Commission with the scientific advice it needs when preparing policy and proposals relating to consumer safety, public health and the environment. The Committees also draw the Commission's attention to the new or emerging problems which may pose an actual or potential threat.

These Committees are: the Scientific Committee on Consumer Safety (SCCS), the Scientific Committee on Health and Environmental Risks (SCHER) and the Scientific Committee on Emerging and Newly Identified Health Risks (SCENIHR).

In addition, the Commission relies upon the work of the European Food Safety Authority (EFSA), the European Medicines Agency (EMA), the European Centre for Disease prevention and Control (ECDC) and the European Chemicals Agency (ECHA).

SCENIHR

This Committee deals with questions related to emerging or newly identified health and environmental risks and on broad, complex or multidisciplinary issues requiring a comprehensive assessment of risks to consumer safety or public health and related issues not covered by other Community risk assessment bodies. Examples of potential areas of activity include potential risks associated with interaction of risk factors, synergic effects, cumulative effects, antimicrobial resistance, new technologies such as nanotechnologies, medical devices including those incorporating substances of animal and/or human origin, tissue engineering, blood products, fertility reduction, cancer of endocrine organs, physical hazards such as noise and electromagnetic fields (from mobile phones, transmitters and electronically controlled home environments), and methodologies for assessing new risks. It may also be invited to address risks related to public health determinants and non-transmissible diseases.

Scientific Committee members

Dr. Michelle Epstein, Dr. Igor Emri, Prof. Dr. Philippe Hartemann, Prof. Dr. Peter Hoet, Prof. Dr. Norbert Leitgeb, Dr. Luis Martínez Martínez, Prof. Dr. Ana Proykova, Dr. Luigi Rizzo, Prof. Dr. Eduardo Rodriguez-Farré, Dr. Lesley Rushton, Prof. Konrad Rydzynski, Dr. Theodoros Samaras, Dr. Emanuela Testai, Dr. Theo Vermeire

Contact:

European Commission
DG Health & Consumers
Directorate C: Public Health
Unit C2 – Health Information
Office: HTC 03/073 L-2920 Luxembourg

Sanco-SCENIHR-Secretariat@ec.europa.eu

© European Union
ISSN 1831-4783
10.2772/76284

ISBN 978-92-79-30135-3
ND-AS-13-005-EN-N

The opinions of the Scientific Committees present the views of the independent scientists who are members of the committees. They do not necessarily reflect the views of the European Commission. The opinions are published by the European Commission in their original language only.

http://ec.europa.eu/health/scientific_committees/policy/index_en.htm

ACKNOWLEDGMENTS

The members of the Working Group are acknowledged for their valuable contribution to this opinion. They are:

SCENIHR members:

Prof. Igor EMRI (SI-Ljubljana) - Center for Experimental Mechanics, Faculty of Mechanical Engineering, University of Ljubljana, Slovenia

Prof. Peter HOET (BE – Leuven) - Department of Public Health, Faculty of Medicine, Experimental Toxicology Unit, Laboratory of Pneumology, Leuven – Belgium (chair of the Working Group since April 2013)

External experts:

Dr. Charles Patrick CASE (GB-Bristol) - University of Bristol, United Kingdom

Prof. Wolfgang DEKANT (DE – Wuerzburg) - Department of Toxicology, University of Würzburg, Germany

Dr. Wim DE JONG (NL – Houten) - Department for Product Safety Centre for HealthProtection, National Institute for Public Health and the Environment, Bilthoven, The Netherlands

Prof. Klaus-Peter GÜNTHER (DE-Dresden) - Chairman and Director University Center of Orthopaedics and Traumatology, University Hospital Carl Gustav Carus Dresden, Technische Universität Dresden, Germany (Rapporteur)

Prof. Arne HENSTEN (NO – Tromsø) - UiT The Arctic University of Norway, Tromsø, Norway (chair of the Working Group until March 2013 and rapporteur)

Prof. Dr.habil. Michael MORLOCK (DE-Hamburg) - Director, Institute of Biomechanics, Director, Hamburg Research Centre for Medical Technology FMTHH, TUHH Hamburg University of Technology, Germany

Dr. Susanna STEA (IT-Bologna) - Medical Technology Laboratory, Istituto Ortopedico Rizzoli, Bologna, Italy

Dr. Catherine VAN DER STRAETEN (BE-Sint-Martens-Latem) - Director of Research, Department Orthopaedics and Traumatology, Ghent University Hospital, Belgiums

Dr. Cees VERHEYEN (NL-Zwolle) - Dept orthopedic surgery and traumatology Isala Hospital, the Netherlands

Prof. Dr. Luigi ZAGRA (IT-Milan) - Istituto Ortopedico Galeazzi IRCCS, Milan Italy

Special acknowledgement goes to Prof. Dr. Michael MORLOCK for the use of the photographs in this opinion.

All Declarations of Working Group members and supporting experts are available at the following webpage:

http://ec.europa.eu/health/scientific_committees/emerging/members_wg/index_en.htm

ABSTRACT

The European Commission asked the SCENIHR for a scientific opinion to assess the safety of Metal-on-Metal joint replacements with a particular focus on hip implants.

Total hip arthroplasty (THA) with a "stemmed" implant refers to a modular implant system which replaces the entire femoral head (either small-head diameter < 36 mm or large-head diameter > = 36 mm) and is fixed by a stem embedded in the femur as well as a cup embedded in the acetabulum. The replaced head, which may be metal or ceramic, is usually connected to the stem in a modular way with a taper/trunnion. If both articulating surfaces (head and cup) of small-head as well as large-head total hip arthroplasty consist of metal, the implant is called "metal-on-metal" (MoM) total hip arthroplasty. In "conventional" THA the head, which can consist of metal or ceramic, is articulating with a bearing surface on the cup side, which either consists of polyethylene or of ceramic. In contrast, the term "hip resurfacing arthroplasty" (HRA) stands for a total hip arthroplasty which simply resurfaces the femoral head (always large-head diameter) and the acetabulum. Head as well as cup of all contemporary HRA implants consist of metal alloys.

Based on the studies available, the conclusions drawn by the SCENIHR include the following:

All types of these MoM hip arthroplasties release metals in terms of particles, ions and/or metallo-organic compounds. The deposition of these substances in body fluids and tissue may lead to local and/or systemic adverse health effects. MoM implants with large diameters (large-head MoM THA and HRA) show the highest incidence of local reactions. For systemic health effects no association with the type of implant or diameter has been established. Local as well as systemic adverse effects can also occur with other types of metallic implants (e.g. plates, screws).

Local tissue reactions: The local responses comprise a broad clinical spectrum ranging from small asymptomatic tissue lesions to severe destruction of bone and soft tissues. These lesions are designated by different terminologies such as: metallosis, ALVAL (aseptic lymphocytic vasculitis associated lesion), pseudotumours, adverse reactions to metal debris (ARMD). These local responses can occur at any time after surgery (short, medium and long term).

Systemic adverse responses: The toxicity of several metals present in implants (e.g. Co, Cr, V, Ti) has been described in laboratory animals and in human epidemiologic studies. Unfortunately, these observations cannot be extrapolated to metal particles, ions, and metallo-organic compounds, which are released at the site of the implant and distributed into lymph nodes, bone marrow and internal organs. There are some specific concerns related to the possible systemic exposure to cobalt and/or chromium after MoM-hip arthroplasty, such as systemic organ toxicity, carcinogenicity and teratogenicity. Although some papers indicate systemic organ effects and an increase in tumour rate, the evidence is insufficient and needs further confirmation. Transplacental passage of metal ions has been demonstrated although without any teratogenic effect up to now. As systematic long-term follow-up studies regarding the risks of MoM THA and HRA are lacking, conclusions are to be considered preliminary.

With regard to follow-up of patients with MoM implants, at present no exact threshold values of critical metal concentrations in blood are available for clinical decision-making. The SCENIHR decided to adopt the strategy as outlined in the European Consensus Statement (Günther et al, 2013). This strategy includes recommendations on technical issues (e.g. metal ion determination for screening purposes should be performed in whole blood) and determination of critical threshold ranges (e.g. for Co a range of 2 - 7 µg/l Co whole blood was defined).

One of these recommendations concerns systematic follow-up for all patients and all implants, due to the risks of MoM bearings. For small-head MoM THA a systematic follow-up similar to conventional THA (regular follow-up with clinical and radiographic investigation at intervals depending on local protocols) is considered sufficient. However, a closer follow-up is recommended for large-head MoM including HRA. For large-head MoM annual follow-up for the life of the joint is necessary. For HRA annual follow-up for at least the first five years is

recommended, then it may be changed to local protocols for patients with conventional THA (if metal ion levels are not significantly elevated). Another recommendation refers to HRA-patients with special risk factors (i.e. small component size, female gender, low coverage arc), for whom annual follow-up for the lifetime of the joint is recommended. However, all patients should undergo clinical as well as radiographic examination during follow-up. Metal ion determination is recommended for large-head MoM THA on a routine basis and for HRA patients at least in the first postoperative years (thereafter depending on their clinical performance it may be changed to THA procedure). In case of clinical and/or radiographic abnormality as well as in case of significantly elevated metal ion levels, additional imaging (ultrasound, CT-scan, and/or MARS-MRI) is recommended. Importantly, these recommendations are based on potential local adverse effects of MoM arthroplasties and not on systemic effects, because threshold values are not yet established.

The following advice can be formulated based on the described potential adverse effects:

Due to the higher health risk when compared with alternative implants, the application of MoM hip arthroplasty should carefully be considered on a case-by case basis.

The subgroup of large-head MoM implants used in THA should be avoided, on the basis of their high failure risk. However, resurfacing may be an option in a highly selected subgroup of patients, i.e. especially young and active male patients with large bony femoral head size (≥ 50 mm) and favourable head-neck-ratio. In women with a bony femoral head size < 50 mm, HRA is a contraindication.

In addition to the specific characteristics of patients and implant types, the expertise of the surgeon also plays a crucial role. Therefore, surgical procedures should only be performed by very experienced and well-trained surgeons. It is of special importance to avoid high cup inclination and high anteversion.

The patient should be also informed about the specific adverse health effects related to MoM implants and should be followed up rigorously.

The experience with MoM to date indicates that introduction of new or technically modified implants on the market should be made step-by-step. It is stressed that proper preclinical and clinical studies are particularly important and that MoM require the close and comprehensive post-market surveillance.

Keywords: Total hip arthroplasty, hip resurfacing, metal-on-metal, metal ions, metal debris, health effects, adverse reaction, pseudotumours, ALVAL, ARMD

Opinion to be cited as:

SCENIHR (Scientific Committee on Emerging and Newly Identified Health Risks), the safety of Metal-on-Metal joint replacements with a particular focus on hip implants, Day Month 2014

TABLE OF CONTENTS

ABSTRACT	4
1. EXECUTIVE SUMMARY	8
2. BACKGROUND	14
3. TERMS OF REFERENCE	14
4. SCIENTIFIC RATIONALE	16
4.1. Introduction	16
4.2. Metal-on-Metal implants	17
4.2.1. Categories of Metal-on-Metal implants	17
4.2.1.1. Metal-on-metal THA	18
<i>Small-head Small-head MoM:</i>	18
<i>Large-head MoM:</i>	18
4.2.1.2. Hip resurfacing (HRA)	18
4.2.2. Metal wear and degradation products	19
4.3. Clinical outcomes	19
4.3.1. Survival rates of MoM-THA	19
4.3.1.1. Small-head MoM THA	20
4.3.1.2. Large-head MoM THA	20
4.3.1.3. Hip resurfacing arthroplasty (HRA)	21
4.3.2. Clinical function and Quality-of-Life after implantation of MoM	22
4.3.3. Potential adverse effects (local and systemic) of MoM implants in comparison to non-MoM implants	22
4.3.3.1. Local adverse effects	23
4.3.3.2. Systemic adverse effects	23
4.3.4. Factors influencing the outcome: surgeon, patient and implant	27
4.3.5. Conclusions	28
4.4. Diagnostic tools needed for clinical decision-making	29
4.4.1. Imaging studies	29
4.4.1.1. Radiographic imaging	29
4.4.1.2. Ultrasound (US) examination	29
4.4.1.3. Computed tomography (CT)	30
4.4.1.4. Magnetic resonance imaging (MRI)	30
4.4.2. Measurements of metal/metal ions in body fluids	31
4.4.2.1. Sample sources	31

4.4.2.2. Protocol for blood sampling.....	31
4.4.2.3. Interpretation of metal ion levels.....	31
4.4.3. Possibility for analysis of synovial fluid and periprosthetic tissue.....	32
4.4.4. Conclusions.....	33
4.5. Metal toxicology	33
4.6. Clinical strategies for the management of patients with implanted MoM.....	34
4.6.1. Recent opinions and comments.....	34
4.6.2. European multidisciplinary consensus statement on the use and monitoring of metal-on-metal bearings for THA and HRA	37
4.6.3. Results of MoM revision surgery	38
4.6.4. Conclusions	39
4.7. Conclusions of MoM implants.....	40
4.7.1. Risk factors for MoM implants	40
4.7.2. Benefit factors for MoM implants	40
4.7.3. Follow-up of MoM implants and induced adverse effects.....	40
4.7.4. Gaps in knowledge.....	41
4.8. Research recommendations.....	42
5. OPINION	44
6. MINORITY OPINION.....	46
7. LIST OF ABBREVIATIONS	47
8. REFERENCES	48
Appendix 1: Detailed description of Metal-on-Metal implants	59
Appendix 2: Selected recommendations for the management of patients with implanted MoM hip arthroplasties from national health authorities and scientific organisations	64

1. EXECUTIVE SUMMARY

In this opinion, total hip arthroplasty (THA) by a "stemmed" implant refers to a modular implant system which replaces the entire femoral head and is fixed by a stem embedded in the femur as well with a cup embedded in the acetabulum. The replaced head, which may be metal or ceramic, is usually connected to the stem in a modular way with a taper/trunnion. In contrast, the term "hip resurfacing arthroplasty" (HRA) indicates a total hip arthroplasty, which simply resurfaces the femoral head and the acetabulum. In addition, it may have a peg (stem) in the femoral neck. The fixation of the hip implants to the bone can be achieved with or without cement.

In the early 1960s, Metal-on-Metal (MoM) hip implants began to replace "conventional" systems consisting of metal-on-polyethylene (MoP) or ceramic-on-ceramic (CoC) joints. Following the introduction of polyethylene as the bearing surface in the acetabulum, the use of the MoM implants were largely stopped. However, at the end of 1980s, MoM implants were reintroduced as a bearing surface for hip arthroplasty to solve the problem of particle-induced osteolysis, which was a side-effect of polyethylene wear. *In vitro* hip-simulator studies demonstrated a substantial decrease in volumetric wear and much smaller particles with MoM compared to MoP. This finding was confirmed in medium- to long-term clinical studies with high-carbon alloy MoM 28-mm and 32-mm total THA hip arthroplasty ("small-head THA"). Promising early results seemed to justify the introduction of additional types of implants with MoM bearings: For example, hip resurfacing arthroplasty (HRA) was introduced with the aim of improving implant survival rates in young and active patients with conventional THA. Subsequently, large diameter metal femoral heads (≥ 36 mm) attached to a femoral stem via a taper/trunnion connection were also introduced ("large-head MoM THA"), as they facilitated HRA revisions for fractured femoral necks and were advantageous because they prevented hip dislocation, which is one of the main postoperative complications in hip arthroplasty.

Product survival rate of MoM implants

An important parameter of successful artificial implant is the survival rate,, which is documented by clinical studies with adequate long-term follow-up as well as in Arthroplasty Registries. Overall, MoM implants are associated with lower survival rates in meta-analyses and registries when compared with THA with other bearings. However, the higher observed MoM-revision rate is mainly caused by the poor survival rates of large-head THA and HRA, if they are not implanted properly.

In this opinion, SCENIHR is in agreement with the full 10-year benchmark of 90% survival rate reported by the National Institute of Clinical Excellence (NICE)(National Institute for Clinical Excellence, 2011).

Small-head MoM THA

For small-head THA with a head diameter of < 36 mm, the 11-year survival rate of MoM implants from registries is comparable to the survival of other hard-on-hard bearings. In clinical studies, the results depend on the type of metal bearing. For example, one product with a very high carbide content resulted in promising 10-year survival rates of 94 – 98%. However, in a recent randomized, clinical study, higher failure rates for aseptic loosening were reported even for this product, when compared with ceramic-on-polyethylene (CoP) bearings. The results of other implants with lower carbide concentrations are considerably worse (up to 18% revision rate at 12-years). In addition, there are case reports about the development of local adverse reactions to metal debris.

High-quality MoM bearings with head diameters of < 36 mm have satisfactory 10-year survival rates, which mostly meet current international benchmarks for the performance of a modern primary joint replacement. However, metal debris may occur even in asymptomatic patients

with small-head MoM implants. No systematic investigation of sufficiently large patient cohorts have addressed the potential risk of adverse reactions in MoM patients.

Large-head MoM THA

In spite of the obligation of manufacturers for post-market follow-up, there are no long-term studies available for large-head MoM THA. However, the high failure rates in short- and medium-term clinical studies documented the poor performance of these implants due to a high incidence of pseudotumour formation. Moreover, some registries confirmed the bad performance of these implants with reports of 10-year cumulative percent revision of MoM-THA with a head diameter of 36mm and more being four times higher (20.3%) than the cumulative percent revision of CoC bearings with a similar diameter. The failures may be caused by a combination of elevated metal ion release and fretting corrosion at the taper due to the large head diameter. Some MoM large-head implants were recalled from the market due to their bad performance.

Hip Resurfacing Arthroplasty (HRA)

The survival rates for HRA are generally better than large-head MoM arthroplasties and lower than stemmed small-head THA. Of note, HRA survival rates are influenced by gender, type and size of implant and surgical factors.

Currently available medium- to long-term studies show an 87% to 95.5% 10-year survival rate. In a recent meta-analysis, none of the implants met the full 10-year NICE benchmark survival rate of 90% (National Institute of Clinical Excellence, 2011), though another review found that 3 implant systems met these criteria. Survival analysis involving 2773 HRA implanted at 11 centers showed a cumulative survival rate of 96.4% at 5 years. The results were better for male compared to female patients. The most common cause of failure was fracture of the femoral neck, followed by loosening of the femoral component.

In summary, the current overall survival rates of HRA are lower than those of conventional implants. A survival rate similar to conventional implants may be achieved in HRA in young male patients with a well-performing type of implant and sufficient head size and correct positioning during surgery,. However, most investigations on prosthesis survival do not take into account the potential of local adverse tissue reactions from metal debris.

Clinical function and Quality-of-Life after implantation of MoM

To date, available data reveal that MoM hip replacement when compared to THA with non-MoM-bearings results in comparable clinical joint function and Quality-of-Life (QoL) Regarding HRA, an improvement of clinical function and QoL over conventional THA has been postulated in the past due to the "anatomical" restoration of the hip joint. Although this could not be confirmed for HRA in general, except in some subgroups of patients i.e. young and active men, HRA shows superior short- to medium-term clinical outcome. .

Potential adverse effects of MoM implants in comparison to non-MoM implants

Potential adverse effects of MoM hip arthroplasty are similar to reactions every patient undergoes with an arthroplasty procedure including thrombosis, wound infection, etc However, MoM arthroplasty is also associated with metal-specific reactions.

All metal implants, and in particular MoM THA, lead to the release of metal products including particles, ions and metallo-organic compounds into body fluids. These subsequently may deposit in lymph nodes, bone marrow and internal organs. MoM implants contain several different metal alloys, which leads to the production of a mix of metallic products. For example, the bearing surface itself is predominantly made from CoCrMo-alloys and may also contain small amounts of nickel (Ni), iron (Fe), manganese (Mn) and silicon (Si). Metal toxicity has been extensively studied and is readily available in toxicology textbooks. However, this information is of limited use in the present context because the metal degradation products have not been adequately characterised and is an important area for further research.

Local adverse effects (characteristic histopathological responses to particles) as well as systemic adverse effects (toxicity, carcinogenicity and teratogenicity) are possible. Additionally, there may be a potential for orthopaedic implants to induce allergic reactions due to metal sensitisation, but the evidence for MoM THA causing allergic responses is not convincing. Therefore, this report concentrates on local and systemic adverse events occurring after MoM hip arthroplasty.

Local adverse effects

Local tissue responses to metal particles around the operated joint have been described grossly as "metallosis"; "aseptic lymphocytic vasculitis associated lesion" (ALVAL) based on a lymphocyte-dominated immunological response within the periprosthetic tissues from MoM hip articulations diagnosed at time of revision; and "pseudotumours", which are cystic/solid masses developing in relation to non "well-functioning" metal prostheses (i.e. patients with hip complaints, clinical and/or radiographic abnormality). However, the current generic all-encompassing term used to describe the local response is "adverse reactions to metal debris" (ARMD). It summarises the histopathology associated with MoM hip arthroplasties including ALVAL, lymphoid neogenesis, granulomatous inflammation and metallosis. The clinical spectrum of ARMD is large and ranges from small asymptomatic cysts to large cystic or solid soft tissue masses (pseudotumours) as well as extensive osteolysis with bone destruction around the prosthesis.

The prevalence of ARMD around poor-functioning MoM-joints is difficult to determine, because the number of properly designed systematic studies is low. The incidence of pseudotumours in large-head MoM THA and HRA, reported in different cohort studies, ranges from 0 – 61%. In a meta-analysis of the incidence of pseudotumours and ALVAL reactions in MoM arthroplasties (total of 13,898 MoM implants), where mainly large-head MoM and resurfacing MoM implants were included, the incidence ranged from 0% to 6.5% of hips with a mean follow-up ranging from 1.7 to 12.3 years across the studies. This was calculated to be a pooled estimated incidence for pseudotumour and ALVAL reactions of 0.6%.

In small-head MoM-THA, the incidence of ARMD seems low, because only a few case reports exist, despite several hundred thousands prostheses have been implanted in the last 3 decades.

Systemic adverse effects

There are specific concerns related to possible systemic exposure to metallic products after MoM hip arthroplasty based on known adverse effects induced by Co and Cr, such as systemic organ toxicity, carcinogenicity and teratogenicity. To date, the data on these adverse effects in patients with MoM prostheses is limited. Moreover, it is difficult to quantify an estimated risk based on ionic blood levels.

Systemic organ toxicity

Theoretically, metal implants may have associated adverse effects in all tissues and organs of the body. However, published evidence on metal-related systemic toxicity in patients with hip arthroplasty and specifically with MoM implants is limited. In some case studies, the potential clinical picture of "arthroprosthetic cobaltism" is highlighted.

In an observational study of 39 hip arthroplasty patients (26 with MoM THA), one patient had a provisional diagnosis of demyelinating neuropathy which markedly improved after revision surgery. Overall, 20 patients underwent revision surgery of their THA and revision was associated with a decrease of metal ion levels in the blood. Patient complaints did not correlate with Co and Cr ion blood levels. In another study of 32 consecutive patients with large-head MoM THA were compared to an age?-matched cohort of 32 patients with MoP THA. Serum metal ion levels, liver and kidney function and host immunologic immune responses were evaluated 2 years postoperatively. The authors observed that mean Co and Cr levels in the large head-MOM group were 4.33-fold and 1.95-fold higher than those in the control group. Clinical scores and liver and kidney function were similar between the groups. However, CD3+, CD4+ and CD8+ cell numbers in the LH-MoM group were significantly decreased, while interferon- γ (INF- γ) levels were increased. In another study, a detailed cross-sectional comparison of 35 asymptomatic patients with MoM HRA and an age?-matched cohort with

conventional THA, increased body bone mineral density and reduced cardiac ejection fraction were found eight years after HRA without any evidence of neuropsychological, renal tubular, hepatic or endocrine function differences. In a detailed clinical screening of 10 asymptomatic patients with very high Co levels of 18-153 µg/L (mean 46.8 µg/L), extensive neurological, cardiac, renal and thyroid function were normal during the 4.2 year follow-up after implantation of a Large-head MoM arthroplasty.

To date, there is no evidence for long-term adverse effects of metal ions derived from MoM implants. A general systematic approach to this problem is needed.

Carcinogenicity

The majority of epidemiological studies have not made a distinction between MoM implants and MoP implants. Few studies have examined long-term risks of exposure taking into account the potential latency of metal-induced effects.

a) General carcinogenicity studies on implants

In two large long-term studies (predominantly of patients with MoP implants), no significant difference in the overall rate of cancer in patients with metal implants was found compared to the general population after short-term follow up.

Data from a large cohort of patients with total knee replacements (TKA) from the Swedish Knee Arthroplasty Registry was used to compare the incidence of cancer to the overall national cancer incidence in Sweden. For all TKA patients, the overall risk of cancer was elevated. The greatest increase in risk was for leukaemia subtypes, myelodysplastic syndromes and essential thrombocytosis. Increase in risk was also observed for breast cancer, prostate cancer and melanoma. The authors also performed an analysis of cancer latency period to identify potential etiological factors. This analysis revealed that increases in myelodysplastic syndrome and possibly prostate cancer and melanoma appeared to be associated with the operation. This study highlights that systemic adverse effects of metal products (whatever the chemical species is) may not only be limited to patients with hip arthroplasty – and especially MoM – implants, but can probably occur also in other patients with any type of metallic implant.

b) Studies focussing on MoM implants

A larger number of chromosomal aberrations (structural aberrations aneuploidy gain) in a MoM patient cohort was observed when compared to individuals without metal implants. The clinical consequences of the observed chromosomal changes are unknown and emphasise the need for additional investigation.

The majority of clinical data can be found in Arthroplasty Registries: Combined data analysis from Nordic registries showed similar overall cancer incidence for all hip arthroplasty patients when compared to the general population. The rate of stomach and colorectal cancer was significantly reduced, while the rate of prostate cancer and skin melanoma was significantly increased in one THA cohort. All-site cancer incidence of a historic “first-generation” MoM implant (McKee-Farrar prosthesis) was not different from the general population after a maximum follow-up of 28 years. An investigation of the same implant in the Finnish Arthroplasty Registry (calculation of standardised mortality ratios of total and site-specific causes of death for 579 patients with McKee-Farrar THA and 1,585 patients with MoP THA after a mean follow-up time of 16-17 years) showed for both THA cohorts decreased mortality for the first decade postoperatively, equal mortality over the next 10 years, and increased mortality after 20 years in comparison to the normal Finnish population. It must be emphasised that wear rate and metal ion release of the historic McKee-Farrar prosthesis are substantially higher than those of modern design MoM implants.

Another investigation looked at contemporary MoM implants, but the follow-up was shorter. The relative risk of cancer in 10,728 patients with MoM-THA after a mean follow-up of 4 post-operative years and 18,235 patients with conventional THA in the Finnish Arthroplasty Register showed that the overall risk of cancer in patients with MoM hip implants was not significantly

different from that in the general Finnish population. A higher than expected incidence of basal cell carcinoma in the MoM-cohort was observed, offset by a lower incidence of lung cancer. These effects may be due to confounding factors (i.e. smoking, body mass index), but these factors have not been analysed in this context.

In two other investigations of UK Joint Replacement Registries, different results are reported. One study was performed at a linked database of hospital discharge, cancer registration and mortality records in Scotland, where indirectly standardised incidence ratios have been calculated for selected cancers in patients with primary THA (MoM THA as well as other bearings, operated in 1990-2009) and MoM HRA (2000-2009). For the analysed population of 71,990 patients and the total period of observation combined, the risks of all cancers, prostate cancer, and multiple myeloma were increased. For the 1,317 patients with MoM HRA, there was no significant increase of SIR for all cancers. A weakness of this study is again the short follow-up time of patients with MoM implants and inadequate adjustment for potential confounding factors. Another group directly compared the incidence of cancer in 40,576 patients with MoM hip arthroplasty and 248,995 patients with alternative bearings, linking the National Joint Registry of England and Wales to NHS hospital episode statistics. They showed neither an overall increased risk of incidence of cancer nor an increase in malignant melanoma and haematological, prostate, and renal tract cancers. However, the mean follow-up of 3 years in this study is short compared to cancer latency time.

Teratogenicity

Although a teratogenic potential of chromium and cobalt is well known, there seems to be no documented clinical cases associated with MoM-implants. Opinions vary as to what extent a transplacental transfer of metal products is possible.

In a cohort of 48 women who had received MoM HRA at childbearing age (40 years or younger at surgery), 11 women reported pregnancies, and 8 returned a survey indicating that no children were born with birth defects and all of them appear to be developing normally. Metal ion levels in these patients were not reported. Further results of larger cohorts are still lacking.

However, due to the potential of transplacental metal ion transfer with unclear consequences, MoM-arthroplasty is not recommended in female patients at childbearing age.

Conclusions of factors influencing the health outcome: surgeon, patient and the implant *per se*

The clinical outcome after MoM hip arthroplasty depends on the type of implant as well as patient and surgeon-specific factors: while the overall long-term survival rates of MoM implants are lower than survival rates of conventional THA implants, only certain subgroups (i.e. well-performing types of small-head MoM THA, and well-performing HRA implants in young male patients) seem to have comparable results. Female gender, small femoral component size and edge loading due to high cup inclination/anteversion are major risk factors.

Regarding the functional outcome and health-related Quality-of-Life, there is no overall difference between MoM implants and conventional THA. Selected subgroups, young and active male patients, conversely, may benefit from HRA.

However, even properly placed MoM implants of high quality (high carbon content and favourable design) release metallic products which can induce local and systemic adverse reactions. As there is still a lack of systematic long-term follow-up studies on the benefit and the risks of MoM THA and HRA, conclusions are preliminary.

The seriousness of case reports on both local soft tissue damages and systemic toxicity seems to suggest the need for being particularly restrictive in implanting the MoM type of prostheses. Registry data of carcinogenicity are still reassuring, as there is currently no evidence of an overall increase in cancer associated with MoM hip arthroplasty. Occasionally reported elevation of hematopoietic malignancy, prostate cancer and melanoma rates in patients with all types of orthopaedic implants confirm the necessity, however, to perform repeated analysis of sufficiently large patient cohorts and longer follow-up.

The application of MoM hip arthroplasty should carefully be considered on a case-by-case basis, due to the potential adverse effects of released metal. While resurfacing may be an option in a highly selected subgroup of patients (i.e. especially young and active male patients with bony femoral head size ≥ 50 mm and favourable head-neck-ratio), the implantation of large-head MoM THA should be avoided in other patient groups.

2. BACKGROUND

A specific category of implants are those used for hip arthroplasty. This treatment is very successful in recovering unrestrained and pain free mobility in patients suffering from diseases such as advanced osteoarthritis, which accounts for about two thirds of all total hip replacements.

A preliminary evaluation indicates that the total number of European patients implanted with Metal-on-Metal hip replacements is above 100.000¹. Given the extensive use of these implants, considerable effort was put into increasing their life span. Since first-generation implants with Metal-on-Metal (MoM) as well as with conventional polyethylene (MoP) bearing articulation demonstrated problems with durability (aseptic loosening due to wear particles is the most frequent reason for revision), alternative hard and soft articulating surfaces were developed to decrease wear. These newer articulating surfaces were engineered from improved materials in optimized designs. Second- and third-generation MoM hip implants, for example, made use of these new joints.

MoM hip replacements offer the potential to decrease wear, but pose additional challenges such as a potential for an increased release of metal particles or ions, including cobalt and chromium. This metal debris can originate either from the bearing articulation directly or from the modular taper junction between prosthesis head and stem. In the past, the taper has only been reported anecdotally as the origin of problems. Recently the taper has emerged as the focus for attention, since large modular metal heads for MoM arthroplasty were introduced due to their ability to reduce dislocation risk, which is the second major complication in hip arthroplasty. These larger heads, however, put larger loads on the taper junction and are suspected to be responsible for the problems suddenly occurring at this side.

Co and Cr are known to be toxic under specific circumstances. The health implications remain unclear, but concerns related to hypersensitivity reaction and subsequent osteolysis, T-cell infiltration and pseudotumour have been raised in a number of recent scientific publications. Long-term effects are still not fully assessed, especially in terms of carcinogenicity, genotoxicity and reproductive toxicity.

Besides their use in hip arthroplasty, metal alloy implants have been used successfully in orthopaedics for years, for example in knee operations and fracture repair. All metal implants are known to release metal ions due to corrosive processes, but some MoM prostheses do so to a much greater extent than previously thought. In the case of total knee arthroplasty, large metal surface areas are present, leading to the possibility of increased release of metal ions.

3. TERMS OF REFERENCE

In the light of the above considerations, the Scientific Committee on Emerging and Newly Identified Health Risks is requested to provide a scientific opinion on 'The safety of Metal-on-Metal joint replacements with a particular focus on hip implants'.

In particular, the SCENIHR is asked:

1. To determine the short-, medium- and long-term local and systemic health effects caused by metal particles, metal ions, and metallo-organic compounds resulting from the implanted medical device and if possible to provide indications on limit values for the metals in any forms.
2. To advise on the predictive value of metal ions in body fluids, clinical strategies and other aspects needed to ensure the safety of implanted patients. Criteria that should inform the medical decision with respect to the implanted patient should be identified where possible.

¹ Based on data from FR, PT, DK, NO, NL, DE, AT, CZ, FI, CH, ES (mainly sales figures)

3. To identify criteria regarding the safety and safe use of MoM implants used in arthroplasty, paying special attention to design and patient groups.
4. Where relevant to identify needs for further research.

4. SCIENTIFIC RATIONALE

4.1. Introduction

In this opinion, total hip arthroplasty (THA) with a "stemmed" implant refers to a modular implant system which replaces the entire femoral head and is fixed by a stem embedded in the femur as well as with a cup embedded in the acetabulum. The cup can consist of a single shell (mostly polyethylene) or a titanium backside together with an articulating insert (made of polyethylene, metal or ceramic). The replaced head, which may be metal or ceramic, is usually connected to the stem in a modular way with a taper/trunnion. In contrast, the term "hip resurfacing arthroplasty" (HRA) indicates a total hip arthroplasty which simply resurfaces the femoral head and the acetabulum. In addition, it may have a peg (stem) in the femoral neck. The fixation of the hip implants to the bone can be achieved with or without cement.

If the articulating surfaces of stemmed THA consist of metal, the implant is called a metal-on-metal (MoM) total hip arthroplasty. As in all contemporary HRA procedures the head as well as the cup consists of metal alloys, they are by definition MoM implants as well. Metal-on-Metal (MoM) hip implants were already used in the early 1960s. Following the introduction of polyethylene, the use of the MoM implants largely stopped, but at the end of 1980s, the MoM implants were reintroduced as a bearing surface for hip arthroplasty to solve the problem of particle-induced osteolysis secondary to polyethylene wear. In vitro hip-simulator studies demonstrated a substantial decrease in volumetric wear and much smaller particles with MoM compared to metal-on-polyethylene (MoP). This finding was confirmed in vivo with high-carbon alloy small-head MoM THA (mostly 28-mm and 32-mm diameter heads). The use of larger-diameter femoral heads (≥ 36 mm) as a solution to postoperative dislocation became possible with alternative bearings such as MoM and ceramic-on-ceramic (CoC) with less apparent wear compared to MoP. Larger heads have effectively reduced the dislocation rate.

Hip resurfacing arthroplasty was introduced with the aim of addressing the inferior survivorship and unsatisfactory clinical results with THA in young and active patients. Early designs of resurfacing with PE cups did not perform well because of rapid wear. Resurfacing with MoM implants was introduced to address this. It was assumed that the anatomical reconstruction of the joint might lead to a better function and higher activity levels compared to THA. Despite the poor results with certain HRA designs and certain populations, some series from designers and independent groups and arthroplasty registers have shown that in some circumstances resurfacing can be similar to (conventional) THA.

MoM large diameter femoral heads (≥ 36 mm) that were similar to the HRA femoral heads but applicable to a femoral stem via a taper/trunnion connection were first introduced to facilitate HRA revisions for fractured femoral necks. They were subsequently used for primary THA because of the apparent advantage with regard to prevention of dislocation.

To date approximately 1 million MoM hip prostheses have been implanted worldwide. These implants are typically composed of Cobalt-Chromium-Molybdenum alloys and other materials including titanium alloys. Wear and corrosion of the bearing and taper surfaces generate metal particles and ions, predominantly cobalt (Co) and chromium (Cr). In addition, other materials, like titanium, could be released as well. Tribological and clinical studies have described a characteristic wear pattern of MoM hips which is initially characterised by a high-wear running-in period, followed by a lower-wear steady-state.

The generation of metal products might lead to severe local adverse soft-tissue reactions as well as potentially systemic adverse events. In cases of increased wear, high levels of metal particles and ions will be released from the wearing articulating surfaces. Particles and ions can also be released from non-articulating surfaces and implants. The use of blood metal level as surrogate markers of metal release from implants is a well-established method and is now recommended as a screening tool for the in-vivo performance of MoM (DeSmet 2008, De Smet 2011, Haddad FS et al 2011, Heisel et al 2008, Kwon et al 2011, Langton et al 2009, Mac Donald et al 2004, Smolders et al 2011). Although smaller diameter (< 36 mm) MoM total hip replacements and some HRA designs have been successful, multiple recent reports have documented markedly increased Co and Cr concentrations in blood and urine which indicates

systemic exposure with poorly functioning MoM hip prostheses (Langton et al 2010, Langton et al 2011, Kwon 2010 Matthies 2012, Kwon 2011, Hart 2011, Van Der Straeten 2012). Besides the local tissue destruction, concerns have also been raised about possible consequences of elevated metal levels in the systemic circulation (Oldenburg et al 2009, Tower 2010, Machado et al 2012, Sotos and Tower 2013, Zywił et al 2013, Chen et al 2013, Prentice et al 2013).

Arthroplasty registry data have revealed that Large Diameter (≥ 36 mm) MoM THA are associated with a high failure rate (Australian Orthopaedic Association National Joint Replacement Registry 2012, National Joint Registry 2013). This may be due to adverse local tissue reactions to metal debris generated either at the bearing articulation or at the taper/trunnion connection. These failing MoM THA with big femoral heads have been shown to cause severe tissue destruction even without highly elevated Co or Cr levels in the blood. This opinion will focus on the issues associated with MoM hip arthroplasty because the problems of MoM are found mostly in hip surgery. Other large-head hip implants may also be associated with clinical problems; however, those will not be reviewed in this opinion.

4.2. Metal-on-Metal implants

4.2.1. Categories of Metal-on-Metal implants

A detailed classification of the different materials and types of Metal-on-Metal implants used in hip arthroplasty is given in the Appendix. In this section a short description of the two categories of implants used is given. These are:

- (1) Metal-on-Metal (MoM) THA:
 - a) Small-head: Modular metal head on a hip stem with a modular metal insert in a metal socket with a head diameter of less than 36 mm (Fig. 1a).
 - b) Large-head: Modular metal head on a hip stem with a metal cup, with a head diameter of 36 mm or more (Fig. 1b).
- (2) Hip Resurfacing (HRA):
 - Metal resurfacing head with a monobloc metal cup (Fig. 1c)

It should be realised that the discrimination between small-heads (< than 36 mm) and large-heads (= or > then 36 mm) is somewhat arbitrary but it is used in most recent literature including the European Consensus Statement (Günther et al 2013, Medicines and Healthcare Products Regulatory Agency 2012).

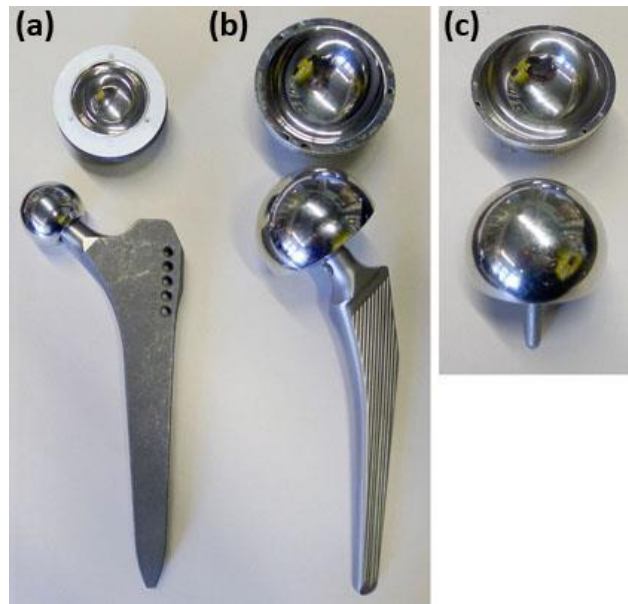


Figure 1: The three groups of contemporary Metal-on-Metal hip joint designs. Left to right: (a) Small-head MoM, (b) Large-head MoM, (c) Resurfacing. The choice of components illustrated is not related to the problems currently observed with certain Metal-on-Metal hip bearing articulations. Manufacturers are therefore not mentioned. Sizes are only examples and represent typical measures. (Source: M.Morlock)

4.2.1.1. Metal-on-metal THA

Small-head Small-head MoM:

In 1998, second generation MoM bearings began being produced (Metasul™, Sulzer, Switzerland). This design with heads of 28mm and 32mm diameter achieved similar or better clinical success than other bearing materials and is still used today. These bearings are typically used in conjunction with a modular uncemented hip stem and a modular uncemented hip socket.

Large-head MoM:

The use of modular metal heads with 36mm diameter and larger is rather recent in MoM arthroplasty. If the head diameter is too large, modular cups are ruled out and monobloc metal cups must be used. Monobloc metal cups are similar to resurfacing cups. This group is the one with the highest reported revision rate, most probably due to issues at the taper connection with large metal heads.

4.2.1.2. Hip resurfacing (HRA)

The revival of resurfacing arthroplasty – after the poor results with the Wagner resurfacing design in the 1970s and 1980s - was driven by Amstutz and McMinn around 1995. Since this time, HR is available only as MoM articulation. After several publications of good short and midterm results, resurfacing became popular very quickly and many companies introduced their own designs into the market. The resurfacing heads are cemented onto a reamed femoral head in most designs; the monobloc cups are used without cement in all designs.

4.2.2. Metal wear and degradation products

Several different metal alloys are used in Metal-on-Metal (MoM) implants. The bearing surface itself is mostly made from CoCrMo-alloys. They may in addition contain small amounts of nickel (Ni), iron (Fe), manganese (Mn), silicon (Si) and vanadium (V).

MoM wear debris may consist of metallic particles produced either by mechanical wear or the products of metal corrosion in the biological environment of the hip joint and surrounding fluid and tissues. In addition, these constituents may dissolve in both intracellular and extracellular solutions, leading to the presence of the ions, which can also be produced directly by corrosion processes (Gill 2011). Presently it is unknown whether ions, particles or metallo organic compounds are responsible for the adverse reactions to the different metal alloys.

4.3. Clinical outcomes

In total hip arthroplasty (THA), one of the most important influencing factors on the longterm success is the tribology of bearing materials, as wear and corrosion can lead to osteolysis and implant loosening. This phenomenon has been extensively studied in conventional polyethylene cups, which have been the most common implants over decades after the introduction of THA (Willert and Semlitsch 1977). As the survival rates of THA with conventional polyethylene cups in young and active patients have not been very good in the past, several alternatives have been introduced (Metal-on-Metal, Ceramic-on Ceramic, highly crosslinked polyethylene).

When compared with other articulating surface materials, MoM seem to have several potential advantages (Hannemann et al. 2013):

- There are no polyethylene particles in pure MoM bearings that may cause inflammation and subsequently osteolysis.
- MoM bearings produce less volumetric wear compared to conventional polyethylene.
- There is a reduced risk of fracture in MoM bearings compared to ceramics.
- MoM is currently the only technique for surface replacement.
- Large-head THA (36mm head size and larger) – often used with MoM bearing - as well as hip resurfacing have a reduced risk of dislocation compared to small-headsmall-head THA (< 36 mm head size). In large-head THA, range of motion increases with the head size (only up to 40mm).
- MoM Hip resurfacing allows more preservation of bone stock on the femoral side when compared to conventional THR.

Due to these proposed advantages, MoM implants of different categories (small and large-head MoM THA, HRA) have been developed and are still in clinical use. The clinical outcomes in these categories of MoM implants are very different as summarized in the following chapter:

4.3.1 Survival rates of MoM-THA

An important parameter of success is the survival rate of artificial implants, which can be documented in appropriate clinical studies with adequate long-term follow-up as well as in Arthroplasty Registries. Only a few long-term clinical studies are available for small-head MoM THA and HRA, but increasing data from National Joint Registries especially in the UK and Australia allows a comparison of all three different MoM-implant categories with other THA devices (Australian Orthopaedic Association National Joint Replacement Registry 2012, National Joint Registry for England and Wales 2010, RIPO Register in Emilia-Romagna, Italy 2012).

MoM implants in general seem to show lower survival rates in meta-analyses as well as in registries when compared to THA with other bearings. For example the revision rate of all MoM implants after 11 years in the Australian Registry is 14,1 %, while the revision rate for non-

MoM-THA is in between 5,1 - 9,5 % (Australian Orthopaedic Association National Joint Replacement Registry 2012). The high MoM-revision rate, however, is mainly caused by the worse survival rates of large-head hip replacements.

4.3.1.1. Small-head MoM THA

For small-head small-head THA with a head diameter of < 36 mm the 11-year revision rate in MoM implants (6,0 %) is comparable to the revision rate of Ceramic-on-Ceramic (5,8 %), Ceramic-on-Polyethylene (9,3 % for conventional PE and 5,7 % for highly crosslinked PE) as well as Metal-on Polyethylene (8,9 %)(Australian Registry, 2012).

In clinical studies the results depend on the type of metal bearing: For Metasul® very promising 10-year survival rates of 94 – 98 % (Grubl et al 2007, Eswaramoorthy et al 2008, Zenz et al 2009) are documented. However, Bjorgul et al (2013) recently reported higher revision rates for aseptic loosening in a randomized study even for Metasul® 28mm heads when compared to ceramic-on-polyethylene bearings. The results of other implants with lower carbide concentrations are significantly worse (Korovessis et al 2006, Milosev et al 2006, Park et al 2005). Repantis et al (2013) observed a revision rate of 18% twelve years after implantation of a cementless THA with a low-carbide bearing surface. In addition, there are reports describing the development of local adverse reactions to metal debris (Baur et al 2005, Gruber et al 2007).

From these investigations it can be concluded that high-quality MoM bearings with head diameters of < 36 mm show a sufficient 10-year survival rate, which mostly meets current international benchmarks for the performance of modern primary joint replacement. However, metal debris may occur even in asymptomatic patients with small-head MoM implants. Therefore it would be necessary to perform adequate screening investigations in order to determine the incidence of adverse tissue reactions in patients who have not undergone revision (see 4.3.3.1).

4.3.1.2. Large-head MoM THA

There are no long-term studies available for large-head MoM THA, but high-revision rates even in short- and medium- term reports document the poor performance of these implants due to a high incidence of pseudotumour formation. Bosker et al (2012) report 39% CT-diagnosed pseudotumours in patients with a revision rate of 12%, 3,5 years after implantation of a Magnum/ReCap®-configuration. Mokka et al (2013) recently performed systematic MRI investigations in a cohort of 77 patients with the same implant and described a 50% rate of ARMD at an average follow-up time of 6.0 (5.5–6.7) years. In the series of Bolland et al (2011) 31 revisions had to be performed in 185 patients with BHR®- and Adept®-implants 5 years postoperatively. Langton et al (2010) describe a revision rate of 6 % for ASR®-implants after 3.5 years due to pseudotumours. More recently, the manufacturer of this device projected a 37% revision rate at less than five years and has recalled this product from the market (<http://www.depuy.com/asr-hip-replacement-recall>). Meyer et al (2012) described the histological investigation of 114 DUROM®-LDH®-explants, which have been revised in an original series of 650 operated patients (805 hips). They conclude that the high failure rate may be due to a combination of elevated metal ion release and fretting corrosion at the taper due to the large-head diameter.

Some registries also provide information about the performance of large-head MoM THA: The Australian Registry (Australian Orthopaedic Association National Joint Replacement Registry 2012) shows that the 10-year cumulative percent revision of MoM-implants with a head diameter of 36 mm and more is four times higher (20.3%) than the cumulative percent revision of Ceramic-on-Ceramic bearings with similar diameter. Recently Mocca et al (2013) have extracted data from the Finnish Arthroplasty Register and compared the risk of revision of 8059 cementless LH-MoM THA to that of conventional small-head metal-on-polyethylene THA total hip arthroplasties. The 7-year unadjusted Kaplan–Meier survival was 96% (95% CI = 95–97) for large diameter MoM THA and 95% (95% CI = 95–96) for conventional THA.

Although there was no significant difference in overall revision risks between MoM and conventional implants, in-depth analyses revealed increased revision rates for LH-MoM in female patients aged 55 years or above as well as for individual implants. An identical observation of higher revision rates of LH-MoM implants with increasing age as well as an influence of the type of implant can be observed in the National Joint Registry of England and Wales (National Joint Registry, 2012).

4.3.1.3. Hip resurfacing arthroplasty (HRA)

Van der Wegen et al (2011) performed a meta-analysis and identified a HRA survival of 84% to 100% in 29 articles (10 621 resurfaced hips) with a mean follow-up from 0.6 to 10.5 years. According to their data, none of the implants met the full ten-year National Institute of Clinical Excellence (NICE) benchmark, which is a survival rate of 90% at a follow-up of ten years. In contrast, Sehatzadeh et al (2012) stated in a more recently performed Ontario Health Technology Assessment with analysis of six different implants that available revision rates for HRA with three implants (BHR®, ConservePlus®, and Cormet®) met the NICE criteria. Two implants had only short-term follow-ups (Re-Cap®, DUROM®) and resurfacing with one of the implants (ASR®) failed to meet the NICE criteria.

The Canadian Arthroplasty Society (2013) recently reported survival rates in a retrospective cohort study involving 2773 HRA at 11 centers. Kaplan–Meier survival analysis showed a cumulative survival of 96.4% (95% confidence interval (CI) 96.1 to 96.9) at five years. The results were superior for male patients (97.4% 5-year survival; 95% CI 97.1 to 97.7) when compared to female patients (93.6% 5-year survival; 95% CI 92.6 to 94.6). The most common cause of failure was fracture of the femoral neck, followed by loosening of the femoral component.

In the meantime long-term studies with a follow-up of at least 10 years have been published with survival rates of 87.0 - 95.5 % (Amstutz et al 2010, Daniel et al 2010, Treacy et al 2011, Hartmann et al 2012). One recent study reports an overall cumulative survival of 94.1% (95% CI 84.9 to 97.3) at 14-year follow-up in patients under the age of 50 years who had received a BHR® HRA (Matharu et al 2013). Murray et al (2013) observed a ten-year survival of 95% (95% CI 92.0 to 97.4) in male patients after implantation of the BHR®. In female patients, however, the ten-year survival was only 74% (95% CI 83 to 91). Mean age of the total cohort at surgery was 51.9 years (16.5 to 81.5).

In most Arthroplasty Registries, however, the survival rates for HRA are generally lower when compared to stemmed THA. Five years postoperatively, the prosthesis survival in the English Registry (National Joint replacement Registry 2010) is 94 % for HRA and 96 – 99 % for conventional THA. The Australian revision rates 11 years postoperatively are 9,5 % for HRA and 7,2 % for conventional THA (Australian Orthopaedic Association National Joint Replacement Registry 2012). Survival in a regional Italian registry at 8 years is 91.5% for HRA and 95.3% for conventional THA (RIPO Register 2012).

Detailed analyses from the Australian Arthroplasty Registry data clearly demonstrate an influence of gender as well as type and size of the implant on the survival rate (Australian Arthroplasty Register 2010 and 2012) : The 7-year-revision rate in female patients (16.9 %) is three times higher than the revision rate in male patients (6.1%). The revision rate for BHR®-resurfacing (5.1%) is similar to conventional THA and significantly lower than the revision rate for the ASR®-prosthesis (23.4 %) as the implant with the worst performance. The 10-year revision rate for HRA with femoral head size ≥ 50 mm is below 5 %, while implants with a head size ≤ 49 mm show a 12 % revision rate.

In summary, the current survival rates of HRA are generally lower than in conventional implants but comparable results may be achieved in young male patients with a well-performing type of implant and sufficient head size as well as correct positioning. Most investigations on prosthesis survival do not take into account, however, the potential of local adverse tissue reactions from metal debris, which can arise even in well performing implants.

4.3.2. Clinical function and Quality-of-Life after implantation of MoM

Due to “anatomical” restoration of the hip joint an improvement of clinical function and Quality-of-Life over conventional THA has been postulated for hip resurfacing in the past. Shimmin and Bare (2011) have indeed shown in a meta-analysis that HRA provides equivalent, if not better functional outcomes in well selected patients (young and active male patients). They highlight, however, that a reported short- to medium-term trend towards superior function and patient satisfaction after HRA, which can be demonstrated in many observational studies, may disappear after matching for age, gender and preoperative function.

Only a few randomized trials exist, where a direct comparison of HRA and conventional THA has been performed. Vendittoli et al. (2010), for example, have shown that at 1 and 2 years post-operatively, patients with HRA achieved statistically significantly better functional scores. However, differences in scores were of slight clinical relevance. Aqil et al (2013) recently demonstrated in a single-blinded controlled study that HRA more closely approximated the gait of the normal control group than THA. Other groups also reported more normal hip kinematics and functionality in HRA (Mont 2007, Benedetti 2012, Shrader 2009), while Petersen et al (2011) did not find any relevant difference to THA in a randomized controlled trial.

For stemmed large-head implants, early reports confirmed the proposed advantages of increased range of motion and lower risk of dislocation due to the increased head diameter on a small neck (Cuckler et al 2004, Sikes et al 2008, Engh et al 2010 Ball ST 2007, Garbuz 2010). However, recent information on poor performances, as stated in the papers above, negates the early suggestions for advantages for these implants. In addition, one recently published study (Zagra et al 2013) shows no difference in gait recovery comparing large-head to small-headsmall-head implants by means of gait analysis.

There are no studies available where either a superior clinical function or better Quality-of-Life has been documented in a direct comparison of small-headsmall-head THA with MoM bearing versus conventional bearings.

While clinical function after MoM THR has been documented in most studies regarding HRA, only a few investigations looked at appropriate health-related QoL measures. Lingard et al (2009) report a significantly greater QoL-improvement in 132 patients with HRA when compared with 214 patients with stemmed THA at one year postoperatively.

Summarizing, there is no general superior clinical function and no better QoL after implantation of MoM hip replacement when compared to THA with non-MoM-bearings. Subgroups of patients (young and active men), however, may show superior short- to medium-term clinical outcomes after HRA.

4.3.3. Potential adverse effects (local and systemic) of MoM implants in comparison to non-MoM implants

Potential adverse effects of MoM-THR can be the unspecific risks every patient undergoes with an arthroplasty procedure (i.e. thrombosis, wound infection, etc) as well as specific risks due to metal exposure (Keegan 2007). As MoM-THA leads to a release of metallic products (i.e. particles, ions, metallo-organic compounds) into body fluids, an accumulation in lymph nodes, bone marrow and internal organs is possible. Local adverse effects (characteristic histopathological response to particles) as well as systemic adverse effects (toxicity, carcinogenicity and teratogenicity) are possible. There is also an ongoing discussion about the potential of orthopaedic implants to induce allergic reactions due to metal sensitization (Cousen 2012, Zeng et al 2013), but the evidence of unspecific allergy and THA is rare. Therefore this report concentrates on specifically occurring local and systemic adverse events after the implantation of MoM hip arthroplasty. Nevertheless, it would be good to develop guidelines on the management of patients receiving metal-on-metal arthroplasties suspected of being metal-allergic (Cousen 2012).

4.3.3.1. Local adverse effects

Local tissue responses to metal particles around the operated joint are possible and have grossly been described as “metallosis” in the past. Willert et al (2005) introduced the concept of “aseptic lymphocytic vasculitis associated lesion” (ALVAL) based on a lymphocyte dominated immunological response within the periprosthetic tissues from metal on metal hip articulations obtained at time of revision. Subsequently, Pandit et al (2008) described the occurrence of “pseudotumours”, which are cystic/solid masses developing in relation to non well-functioning metal prostheses (i.e. patients with hip complaints, clinical and/or radiographic abnormality). In a recent article, Natsu et al (2012) developed a generic all encompassing term “adverse reactions to metal debris” (ARMD), which summarizes the histopathology seen in association with metal on metal hip arthroplasties including ALVAL, lymphoid neogenesis, granulomatous inflammation and metallosis.

The clinical spectrum of ARMD is large and ranges from small asymptomatic cysts to large cystic or solid soft tissue masses (pseudotumours) as well as large osteolyses with bone destruction around the prosthesis (fig.2). Diagnosis of tissue destruction is possible through radiographs and/or ultrasound examination, computed tomography (CT) and MRI with metal artifact reduction sequence (MARS-MRI).

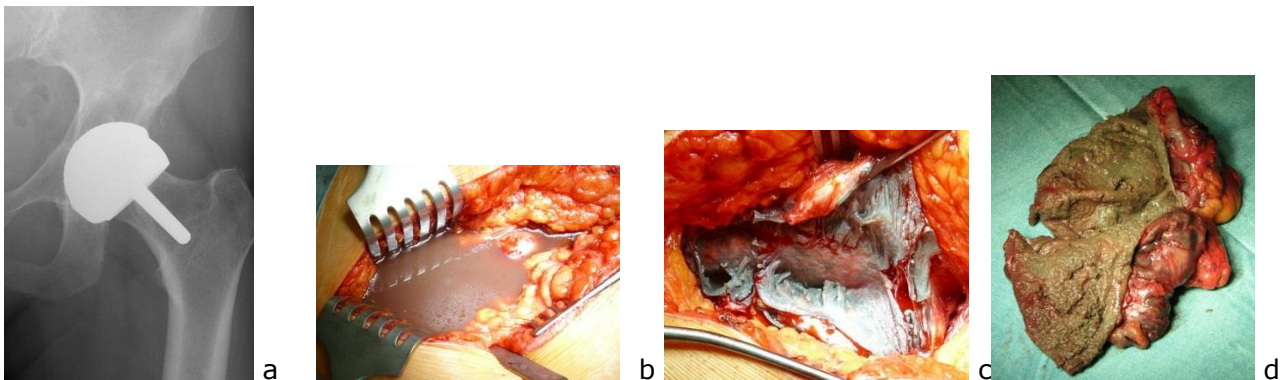


Fig. 2: Osteolysis (superiorly to the acetabular component, a) and different formations of cystic/solid soft tissue masses in ARMD (b, c, d) (Source: M.Morlock)

The prevalence of ARMD around MoM-joints is difficult to determine, as the number of systematic studies with appropriate design is still very small. Therefore the published incidence of pseudotumours in large-head MoM THA and HRA ranges from 0 - 61% in different cohorts (Bisschop et al 2013, Kwon et al 2010, Matthies et al 2012, Williams et al 2011, Daniel et al 2012). The large spectrum of pathological findings is probably due to different type/size of implants, different imaging tools and a selection of symptomatic patients (non well-functioning cases) versus cross-sectional screening in asymptomatic patients. Wiley et al (2013) recently performed a meta-analysis of 14 published reports on the incidence of pseudotumours and ALVAL reactions in MoM arthroplasties (total of 13,898 MoM implants). Mainly large-head and resurfacing MoM implants were included. The incidence of pseudotumour/ALVAL ranged from 0% to 6.5% of hips with a mean follow-up ranging from 1.7 to 12.3 years across the studies. They calculated a pooled estimated incidence for pseudotumour/ALVAL of 0.6% (95% CI: 0.3% to 1.2%).

In small-head MoM-THA the incidence of ARMD seems to be very low, as only a few case reports exist (Baur et al 2005, Gruber et al 2007), although several hundred thousands prosthesis have been implanted in the last three decades.

4.3.3.2. Systemic adverse effects

There are some specific concerns related to the possible systemic exposure to cobalt and/or chromium after MoM hip arthroplasty, such as systemic organ toxicity, carcinogenicity and

teratogenicity. Until now, the database for these three effects in patients with MoM prosthesis has been small. Due to the complexity of the exposure to the metallic products including particles, ions and still uncharacterized metallo-organic compounds, it is difficult to perform a quantitative estimate of the risk on the basis of ionic blood levels, referring to the toxicological profile of single metals. Metal products released into body fluids are deposited in lymph nodes, bone marrow and internal organs. Therefore it is extremely difficult to define the exact risk of systemic adverse effects.

Systemic toxicity:

The published evidence on metal-related systemic toxicity in patients with hip arthroplasty and especially MoM implants is rather limited. In some case studies the potential clinical picture of "arthroprosthetic cobaltism" is highlighted (Oldenburg et al 2009, Tower 2010, Machado et al 2012, Sotos and Tower 2013, Zywił et al 2013). Tower (2010) reported two patients with Articular Surface Replacement (ASR) implants. Massively elevated anteversion in one case and a significant mismatch of head- and shell-diameter in the second case due to surgical faults resulted in severe abrasive wear and cobalt serum ion elevation (up to 122 µg/L). The patients reported anxiety, headache, irritability, fatigue, tinnitus, hearing loss, cognitive decline, and depression. Most symptoms improved after revision surgery. There is impressive evidence from a case report of a broken ceramic head with revision to metal on polyethylene THA (Oldenburg et al 2009). High levels of cobalt due to massive deterioration of the metal femoral head caused by overlooked particles of the broken ceramic head led to hypothyroidism, peripheral neuropathy, and cardiomyopathy. Most of the symptoms disappeared after second revision and replacement of the scraped metal head. Another patient even recently died due to cobalt-induced cardiomyopathy six months following revision of a fractured ceramic-on-ceramic total hip replacement to a metal-on-polyethylene bearing. Massive weight loss of the metal head as a result of severe abrasive wear by ceramic particles embedded in the revision polyethylene liner led to a peak whole blood cobalt level of 6521 µg/L (Zywił et al 2013).

Leikin et al (2013) performed an observational study of 39 hip arthroplasty patients (26 of them having MoM THA), who were investigated at two outpatient medical toxicology clinics. Twelve patients were symptom-free, nine complained of fatigue and two other patients had been previously diagnosed with fibromyalgia. A major complaint was tinnitus/hearing loss in 12 patients, but no difference between the incidence of this symptom in MoM and non-MoM patients could be observed. Of three patients with provisional diagnosis of demyelinating neuropathy, one patient experienced marked improvement after revision surgery. Overall, 20 patients underwent revision surgery of their THA and surgery was associated in a decrease of metal ion levels. Patients subjective complaints, however, did not correlate with Co and Cr ion levels.

Two recent investigations systematically looked into potential systemic sequelae of MoM hip arthroplasty (Chen et al 2013, Prentice et al 2013): Chen et al (2013) studied 32 consecutive patients with a large-head MoM THA and compared their results to a matched cohort of 32 patients with metal-on-polyethylene THA with a mean follow-up of two years postoperatively. Serum metal ion levels, liver and kidney function and host immunologic immune responses were evaluated throughout the observation period. Mean Co and Cr levels in the LH-MoM group were 4.33- and 1.95-fold higher than those in the control group. Clinical scores as well as liver and kidney function parameters did not show any difference between the groups. CD3+, CD4+ and CD8+ cell levels in the LH-MoM group were significantly decreased, the INF-γ level was increased. Although this study revealed that subtle immunological changes can occur after MoM implantation, it is doubtful if these abnormalities are able to compromise host defence mechanisms which may play a role in foreign body reaction to metal products. Prentice et al (2013) performed a detailed cross-sectional health screening in 35 asymptomatic patients with MoM HRA eight years after implantation and compared the results to a matched cohort of 35 asymptomatic patients after conventional THA. They found an increase of body bone mineral density by 5% and a decrease of bone turnover by 14% in the MoM group. The cardiac ejection fraction was 7% lower (mean absolute difference 25%, P = 0.04) and left ventricular end-diastolic diameter was 6% larger (mean difference 2.7 mm, P = 0.007) in the resurfacing group. There was no evidence of difference in neuropsychological, renal tubular,

hepatic or endocrine function between the two cohorts. The authors conclude that chronic exposure to metal concentrations in patients with even well-functioning MoM hiparthroplasty may have systemic effects.

In several cross-sectional surveys evaluating kidney function after MoM THA and HRA the authors did not report any clinically relevant impairment even after long follow-up times (Grubl 2007, Yang 2011, Daniel 2010, Marker 2008). In patients with chronic kidney failure and MoM-THA, only minor elevation of cobalt and normal chromium values have been documented (Hur 2008).

Van Lingen et al (2013) recently published a detailed clinical screening of ten asymptomatic patients with very high Co levels of 18-153 µg/L (mean 46.8 µg/L) at a mean follow-up time of 4.2 years after implantation of LH-MoM arthroplasty. Extensive neurological and cardiological investigations as well as laboratory assessment of renal and thyroid function have been performed. The authors could not identify any signs or symptoms of neurological dysfunction, cardiomyopathy, or renal or thyroid dysfunction in the cohort.

At the moment, the long-term effects of metal ions derived from MoM implants are not known. A general systematic approach to this problem is needed.

Carcinogenicity:

Only a few studies have examined the long term risks of exposure taking into account the potential latency of metal induced effects.

a) General studies

The two largest long-term studies, predominantly of patients with metal on polyethylene implants, have been a meta-analysis of 9 studies by Onega et al. (2006), which included 175,166 patients, and an analysis by Visuri et al. (2010) with 24,636 patients. There was no significant difference in the overall rate of cancer of patients with metal on polyethylene implants from that in the general population after short-term follow up but a slight increase with time post-operatively. Immediately after surgery, the incidence of cancer of the gastrointestinal tract and lung was much reduced, which might reflect less smoking in patients fit for surgery coupled with treatment with non-steroidal inflammatory drugs, which are protective for colorectal cancer. In contrast, the incidence of cancer of bladder, kidney and melanoma was not affected immediately after operation but had increased by 5-9 years (bladder 1.13) and 10+ years (kidney 1.22, melanoma 1.43) in the Onega study and similarly in the Visuri study from 0-2 years (kidney 0.91, melanoma 0.88) to 20+ years (kidney 1.65 melanoma 1.84). Visuri and his study group also published extended data on a large Scandinavian cohort of patients not only with total hip (THA) but also total knee arthroplasty (TKA). Two groups of 49,000 THA patients and 24,000 TKA patients were partly adapted and combined for meta-analysis at a mean and maximum follow-up time of 6.8 and 30 years, respectively. Standardized incidence ratios (SIRs) for the observed number of cancers in the arthroplasty cohorts were compared with expected rates based on national incidence. The overall SIRs as well as the site-specific ones were similar in the THA and TKA patients. The observed number of cancers at all sites was lower in the arthroplasty cohort than the expected one in the normal population. The SIRs for lung cancer (0.69, 95% CI 0.64-0.75), laryngeal cancer (0.64, 0.44-0.92), cancers of the stomach (SIR 0.76, 0.67-0.84), colon (SIR 0.86, 0.79-0.93) and rectum (SIR 0.89, 0.80-0.98) was also reduced. Among TKA patients, the only increases in SIRs were seen in cancers of the endometrium (SIR 1.36, 1.05-1.74), prostate (SIR 1.19, 1.02-1.38) and, among both THA and TKA patients, in skin melanoma (combined SIR 1.21, 1.03-1.41).

Wagner et al (2011) analysed data from a large cohort of patients with knee replacement from the Swedish Knee Arthroplasty Registry and compared the incidence of cancer to the overall national cancer incidence in Sweden. For all TKA patients the overall cancer risks were elevated, ranging from 1.10 (95% confidence interval (CI):

1.03-1.18) for men with primary osteoarthritis to 1.26 (1.23-1.29) for men with rheumatoid arthritis. The greatest increases in risk were observed for the leukaemia subtypes, myelodysplastic syndromes and essential thrombocytosis. Increases in risk were also observed for breast cancer, prostate cancer and melanoma. The authors also performed an analysis of cancer latency period in order to identify potential aetiological factors. This analysis revealed that increases in myelodysplastic syndrome and possibly prostate cancer and melanoma rates appeared to be connected to the operation. This study highlights the fact that a potential release of metal products and an association with systemic adverse effects is not only limited to patients with hip arthroplasty – and especially MoM-implants – but can probably occur also in other patients with all types of metallic medical implants.

b) Studies focussing on MoM implants

Dunstan et al (2008) have found a larger number of chromosomal aberrations (structural aberrations aneuploidy gain) in a MoM patient cohort when compared to individuals without metal implants. They summarize, however, that the clinical consequences of the observed chromosomal changes are unknown and emphasize the need for additional investigations.

Visuri and co-authors published several studies where patients with MoM hip arthroplasties as well as other bearings have been compared to the general population in Scandinavian countries (Visuri et al 2006, Visuri et al 2010, Mäkelä et al 2012): Combined data analysis from Nordic registries (Visuri et al 2006) showed extended life expectancy and similar overall cancer incidence for all hip arthroplasty patients when compared to the general population. The rate of stomach and colorectal cancer was significantly reduced, while the rate of prostate cancer and skin melanoma was significantly increased in the THA cohort. All-site cancer incidence of a historic “first-generation” MoM implant (McKee-Farrar prosthesis) was not different from the general population after a maximum follow-up of 28 years. The same prosthesis was analysed in a consecutive investigation (Visuri et al 2010): standardized mortality ratios (SMR) of total and site-specific causes of death for 579 patients with McKee-Farrar THA and 1585 patients with metal-on-polyethylene THA after a mean follow-up time of 16-17 years have been calculated. In comparison to the normal Finnish population both cohorts showed decreased mortality for the first decade postoperatively, equal mortality over the next 10 years, and increased mortality after 20 years. The overall SMR was 0.95 for the MoM cohort and 0.90 for the metal-on-polyethylene THA cohort. MoM patients had higher cancer mortality (SMR 1.01) than those with metal-on-polyethylene THA (SMR 0.66) during the first 20 years postoperatively, but not thereafter. The authors conclude that both implants are safe based on total and site-specific mortality of recipients during the study period. Although this conclusion is limited by a relatively small cohort size, it is important to note that wear rate and metal ion release of the historic McKee-Farrar prosthesis are substantially higher than those of modern design MoM implants. Mäkelä et al (2012) recently calculated the relative risk of cancer (expressed as the ratio of observed to expected number of cases from the Finnish population) in 10,728 patients with MoM-THA after a mean follow-up of four post-operative years and 18,235 patients with conventional THA in the Finnish Arthroplasty Register. In this investigation the overall risk of cancer in patients with MoM hip implants was not significantly different from that in the Finnish population. They observed a higher than expected incidence of basal cell carcinoma in the MoM-cohort, offset by a lower incidence of lung cancer. According to the authors, these effects may be due to confounding variables, as relevant influencing factors (i.e. smoking, body mass index) have not been analysed.

In two other investigations of National Joint Replacement Registry data, an analysis of large patient cohorts has been performed: Brewster et al (2013) published a linked database of hospital discharge, cancer registration, and mortality records in Scotland, where indirectly standardised incidence ratios (SIRs) have been calculated for selected cancers in patients with primary THA (MoM THA as well as other bearings, operated in

1990-2009) and MoM HRA (2000-2009). For the analysed population of 71,990 patients and the total period of observation combined, the risks of all cancers (SIR: 1.05; 95% CI: confidence interval 1.04-1.07), prostate cancer (SIR: 1.07; 95% CI: 1.01-1.14), and multiple myeloma (SIR: 1.22; 95% CI: 1.06-1.41) were increased. For the 1317 patients with MoM HRA, there was no significant increase of SIR for all cancers (1.23; 95% CI: 0.87-1.68). A weakness of this study is again the short follow-up of patients with MoM implants and inadequate adjustment for potential confounding factors. Smith et al (2012) directly compared the incidence of cancer in 40,576 patients with MoM hip arthroplasty and 248,995 patients with alternative bearings, linking the National Joint Registry of England and Wales to NHS hospital episode statistics. They found neither an overall increased risk of a diagnosis of cancer nor an increase in malignant melanoma or haematological, prostate, and renal tract cancers. The mean follow-up of three years in this study is again very short.

Teratogenicity:

Although a teratogenic potential of chromium and cobalt is well known, there are no documented clinical cases at the moment. Different opinions exist regarding the extent to which a transplacental transfer of metal products is possible. Ziaee et al (2007) as well as deSouza et al (2012) observed a trans-placental passage of metal ions in women with HRA, but the ion levels in newborns were significantly lower than the levels in their mothers' blood. Both authors could not identify any teratologic effects. One other study (Brodner et al 2004) did not find elevated metal ion levels in newborns at all after small-head MoM THA in their mothers. Johnson et al (2013) recently described their experience with a cohort 48 women who had received MoM HRA at childbearing age (40 years or younger at surgery). Eleven women reported pregnancies, and eight returned a survey indicating that no children were born with birth defects and all of them appear to be developing normally. No serum ion levels in these patients were reported. Further results of larger cohorts are still lacking. A clear limitation of all investigations to date is that no measurement of cord blood was performed in female patients with extremely high metal ion levels. Due to the potential of transplacental metal ion transfer, therefore, MoM-arthroplasty is not recommended in female patients of childbearing age.

One study has analysed potential teratogenic effects in male patients: Nikolaou et al (2013) determined Co and Cr concentrations in both the seminal plasma and blood of 11 young male patients with MoM hip arthroplasty as well as in a control group (n=4). The cobalt level was higher in the seminal plasma of (2.89 µg/L) compared to control patients (1.12 µg/L) (P = .011). The clinical implication of this finding, however, is unclear at the moment.

4.3.4. Factors influencing the outcome: surgeon, patient and implant

Recent studies have shown that surgical positioning of MoM implants is closely associated with outcome: from biomechanical investigations and clinical studies of HRA cohorts it is well known that edge-loading and microseparation/subluxation are main triggers for accelerated wear and metal particle release (Griffin et al 2010, Langton et al 2011). Therefore it is critical to achieve a good cup position with inclination below 50° and anteversion of 10-20°. An implant position outside this "safe zone" is correlated with higher serum ion concentrations and increasing risk of pseudotumour formation (De Hahn et al 2008, Desy et al 2011, Langton et al 2011, Hart et al 2011, Hartmann et al 2013).

Several observational studies after implantation of MoM HRA, as well as analyses from Arthroplasty Registries, have also revealed patient-related risk factors for poor outcomes: These include being female (Hart et al 2011, Australian Registry 2011, National Joint Registry 2011, Hartmann et al 2013, Sehatzadeh et al 2012), and particularly being female and less than 40 years of age (Glyn-Jones et al 2009). Ten years post-operatively the revision rate in Australian female patients (16.9%) is nearly three times higher than the revision rate in male patients (6.1 %)(Australian Arthroplasty Register 2012). It is not clear why women generally

seem to have a higher revision rate than men. Contributing factors could be allergic predisposition, increased range of motion (more likely leading to impingement) and different gait patterns (Glyn-Jones et al 2009). Inferior results for female patients could also at least partially be attributed to lower femoral head sizes. It is well known that small implant diameters are associated with the poorest outcome. This is mainly due to a reduced functional arc coverage, which negatively influences the load transmission in small diameter implants (Griffin et al 2010). The Australian Registry shows a 10-year revision rate for HRA with femoral head size ≥ 50 of under 5 %, while implants with a head size ≤ 49 mm have a 12 % revision rate (Australian Orthopaedic Association National Joint Replacement Registry 2012). Although the effect of femoral component head size is independent from gender, female patients tend to receive smaller implants than men. Another independent risk factor for poor outcome is patient age, as there is a higher rate of revision for patients above the age of 65 years (Australian Arthroplasty Registry 2012). This difference can only be observed in the first six months after surgery, where femoral neck fractures are a main cause of failure. Regarding the influence of physical activity on survival rates, the results are controversial, as some studies report positive associations (Desy 2011, Langton 2009) and some report negative associations (Daniel 2009, Vendittoli 2007). It is also unknown if the risk factors for inferior outcome in MoM HRA as discussed above also apply to small-head and large-head MOM arthroplasties.

Several recent studies have shown that the implant per se is influencing the amount of metal particle release and also clinical outcome: Small-head MoM THA Metasul® implants show better survival than implants consisting of other materials (Grubl et al 2007, Eswaramoorthy et al 2008, Zenz et al 2009, Korovessis et al 2006, Milosev et al 2006, Park et al 2005, Repantis et al 2013). For resurfacing implants, the Australian Arthroplasty Registry (2012) as well as clinical studies (Langton et al 2009, Langton et al 2011) and a health technology assessment (Sehatzadeh et al 2012) also report different survival rates depending on the type of implant. In the Australian registry the seven-year implant revision rate is 5.1% for BHR®, 9.3% for DUROM®, 12.4% for Cormet® and 23.4 % for ASR®. As extremely bad results for the latter implant have also been documented in clinical studies (Langton et al 2011), the prosthesis has meanwhile been withdrawn from the market. Design characteristics as well as material properties may be responsible for the different performance of individual implants (Griffin et al 2010, Langton et al 2011). Currently the BHR® prosthesis is still performing very well in the Australian Registry with an overall survival rate of 92.9% at 11 years post-operatively (Australian Arthroplasty Registry 2012).

4.3.5. Conclusions

The product survival rates and local adverse reactions after MoM hip arthroplasty depend on the type of implant as well as patient and surgeon specific factors: While the overall long-term survival rates of MoM implants are lower than the survival rates of conventional THA implants, certain subgroups (i.e. well-performing types of small-head MoM THA and well-performing HRA implants in young male patients) seem to have comparable results. In HRA, female gender, small femoral component size and edge loading due to high cup inclination/anteversion are major risk factors for poor product survival and the development of local adverse reactions. Even well-functioning MoM implants, however release metal particles, which can induce local as well as systemic adverse reactions.

Regarding the functional outcome and health-related Quality-of-Life, there is no overall difference between MoM implants and conventional THA. Selected subgroups (young and active male patients), however, may profit from HRA.

As there is still only a limited number of systematic long-term follow-up studies regarding the benefit and the risks of MoM THA and HRA, conclusions are preliminary. The seriousness of some case reports of both local soft tissue damages and systemic toxicity would suggest that particular prudence is called for in implanting the MoM type of prostheses. Registry data of carcinogenicity are still reassuring, as there currently is no evidence of an overall increase in cancer associated with MoM hip arthroplasty. Occasionally reported elevation of hematopoietic malignancy, prostate cancer and melanoma rates in patients with all types of orthopaedic

implants confirm the necessity, however, to perform repeated analyses of sufficiently large patient cohorts and longer follow-up.

4.4. Diagnostic tools needed for clinical decision-making

In addition to the clinical investigation, the classical imaging tools like X-rays, ultrasound, MRI and CT are available for the follow-up of hip arthroplasty. As MoM implants release metal particles and ions, their level can be determined in various liquids/media (mainly blood, serum and urine and possibly also in hair or nails) which may prove useful in the decision process regarding the implant revision.

4.4.1. Imaging studies

Imaging techniques in MoM THA as well as HRA are applied in order to determine structure and function of implants, periarticular tissues and/or internal organs which may be affected by metal products. Indications for the application may be either routine follow-up examinations in asymptomatic patients or a search for potential adverse events in symptomatic patients. The most commonly used imaging techniques are radiographs, ultrasound (US), computed tomography (CT) and magnetic resonance imaging (MRI). This chapter will focus on diagnostic imaging of implants and periarticular tissues; organ-related diagnostic assessment follows the principles of involved medical specialties (e.g. cardiology, nephrology, neurology).

4.4.1.1. Radiographic imaging

The basis of every diagnostic assessment after MoM THA as well as HRA is a conventional radiograph (antero-posterior pelvic radiograph and lateral view). It is appropriate in routine follow-up investigations as well as in symptomatic patients. The goal of the radiographic investigation is to obtain information on the implant (e.g. type of the implant, bony fixation, position, potential wear) and the quality of periarticular bone (e.g. lucency, osteolysis, osteoporosis) on the femoral as well as acetabular side. Plain radiographs are useful in symptomatic patients to assess component position and detect femoral neck fracture, aseptic loosening, heterotopic ossification or bone destruction from ARMD (Fang et al., 2008). While radiographs of small-head and large-head MoM THA as well as the acetabular component of HRA can be assessed similarly to conventional THA, femoral components of HRA require different evaluation protocols. Instead of a large stem extending over the metaphysis into the femoral canal in conventional THA there is only a small peg which reaches into the metaphysis. In addition the metallic femoral implant overlies the junctions between bone-cement and cement-prosthesis, which impairs the assessment of interactions between bone and cement. The short peg can be used, however to determine periprosthetic bone quality (assessment of lucencies around the peg) and positioning of the implant.

While plain radiographs are important to assess implant position and bone quality, they cannot display potential soft-tissue destruction associated with MoM implants (Toms et al 2008, Duggan et al 2013, Rahman et al 2011, Chen et al 2011).

4.4.1.2. Ultrasound (US) examination

Patients with unexplained pain and normal radiographs require further imaging of the soft tissues. Ultrasound is an accurate method of assessing soft tissue pathology and may be used effectively in the assessment of the painful hip after MoM hip arthroplasty (Siddiqui et al 2013). Prior to CT and/or MRI, US is a simple and safe investigation technique if the examiner is appropriately trained. Several investigators (Pandit et al 2008, Williams et al, 2011, Kwon 2011, Garbuz et al 2013) have shown that ultrasound is capable of detecting pseudotumours associated with MoM implants. Garbuz et al (2013) compared US with MRI for pseudotumour detection in asymptomatic MoM patients and found a sensitivity of 100% and specificity of 96% for US. They conclude, that US is a cost-effective screening tool to rule out pseudotumours in pain-free patients with well-functioning prostheses.

Although image quality of a deep structure such as a suspected peri-prosthetic pseudotumour or fluid collection is dependent on several factors (i.e. experience of examiner, technical equipment, size of patient and lesion) an adequate examination can be achieved with the use of the appropriate US probes and careful technique. Besides the presence of pseudotumours and fluid collections, trochanteric bursitis, heterotopic ossification and femoral neck thinning can also be diagnosed. US is also useful to guide the aspiration of hip intra-articular fluid or a peri-prosthetic cyst or bursa.

The main limitation, however, is that US must be considered as a highly investigator-dependent technique. The inter- as well as intraobserver reliability of sonographic pseudotumour diagnosis has not been proven in any investigation to date.

4.4.1.3. Computed tomography (CT)

CT scan is a well-established diagnostic method for detecting and quantifying peri-prosthetic osteolytic lesions, especially in the acetabulum where they may be difficult to detect on plain radiographs because of the overlying prosthetic cup. CT scans can also detect and delineate solid or cystic masses adjacent to a MoM THA or HRA, both on axial and coronal images reformatted for reduction of metal artifacts (Duggan et al 2013). In the diagnosis of pseudotumours, the sensitivity of CT investigations seems to be comparable to MR imaging (Bosker et al 2012). A CT grading system for describing capsule abnormalities has recently been developed and seems to show good interobserver reliability (Boomsma et al 2013). CT is also utilized to assess acetabular cup position (i.e. anteversion) as a major influencing factor on implant wear and metal ion release. In addition to the diagnostic value of CT, it can be used for imaging guidance when performing aspirations or biopsies. CT examinations always expose the patient to additional radiation dosage. The latest technical developments, however, especially the iterative post processing techniques of various vendors, significantly reduce the patients' exposure to radiation.. The latest metal artifact reduction software by various vendors is capable of improving image quality with improved visibility of the capsule, making it easier to detect pathology due to the reduction of the metal artifacts caused by the metallic components of the implants. Furthermore, CT is capable of assessing bone mineral density of the acetabulum roof with the use of special techniques (Mueller et al 2009).

4.4.1.4. Magnetic resonance imaging (MRI)

MRI is the current gold standard for the identification and detailed description of soft tissue abnormalities. In MoM implants, however, special MRI techniques are necessary in order to reduce metal artifacts: Metal Artifact Reduction Sequence (MARS) MRI can produce diagnostic quality images of periprosthetic bone and soft tissues lesions following MoM hip arthroplasty (Duggan et al 2013). Soft tissue lesions associated with MoM hip arthroplasty have characteristic features on MRI: they appear either as cystic fluid collections confined by a pseudocapsule, or solid masses which are more difficult to delineate. Magnitude, location of the lesion, communication with the hip joint and invasion or destruction of surrounding structures can be accurately assessed. According to Garbuz et al (2013), MRI has a sensitivity of 92% and a specificity of 100% in the detection of pseudotumours. Synovial volume on MRI may also reflect the degree of adverse local tissue reaction (Nawabi et al 2013) in the absence of pseudotumours. Although MRI also allows for evaluation of neighbouring bone, muscle and tendon, the MRI images are sometimes not specific enough to differentiate between wear-induced lesions, infections or some neoplastic pathologies. In those cases, gadolinium-enhanced MR imaging and additional tests such as cultures of aspirated fluid or histological examination of biopsy material may be necessary.

Anderson et al (2011) have developed a reliable MRI grading system for the severity of soft tissue changes associated with MoM THA, which depends on the presence and size of periprosthetic soft tissue masses or fluid-filled cavities, muscle or bone marrow edema and tendon avulsion. According to this classification, normal post-operative appearances and infections are distinguished from "mild", "moderate" and "severe" MoM disease.

4.4.2. Measurements of metal/metal ions in body fluids

4.4.2.1. Sample sources

For the assessment of metal ion levels in patients with a MoM hip prosthesis various matrices, such as whole blood, serum, urine and hip fluid may be used. Analyses in whole blood or serum are preferable, since the metal ion concentrations in urine samples are variable and depend on the hydration of the patient, unless corrected for creatinine content. Twenty-four hour urine concentrations are more reliable but a 24-hour urine collection is cumbersome and often incomplete. Urine samples should be collected avoiding metal contamination as well. Although there is a good correlation between blood and 24-hour urine values, blood is definitely the matrix of choice for routine use, either whole blood or serum. There is no consensus to date on which matrix (whole blood or serum) is superior and both matrices are used in routine clinical practice. Serum or plasma as a source is less complete since the intracellular Cr ions, particularly in the red blood cells (RBC), are not included.

Practically, it is very important to be consistent in using the same matrix when comparing consecutive metal ion values of the same patient or when comparing values of different patients or from different centres.

Analytical methodology

Levels of cobalt and chromium are measured using an inductive-coupled plasma mass spectrometry (ICP-MS) technique. Other measuring analytical methods like Graphite Furnace Atomic Absorption Spectrophotometry (GFAAS) can be used but ICP-MS is known to have lower detection limits and the possibility for simultaneous multi-element determination.

One of the major technical challenges of biological metal ion testing is the risk for contamination from needles, collection tubes or containers and thus rigorous protocols and controls are advocated for every step of the process.

The use of 'trace elements collection tubes' either without anticoagulants or with K₂EDTA is recommended. Transfer pipettes, and other disposables if necessary, must be pre-washed with 0.5 % (v/v) nitric acid and rinsed with distilled water.

Sample volume needed for metal ion analysis

1 millilitre (mL) of serum or plasma and 2 mL of whole blood is sufficient for analysis. A 5 mL urine fraction taken either from a urine sample or a 24-hour collection is sufficient for analysis and back-up storage.

4.4.2.2. Protocol for blood sampling

It is preferable to use a non-metal needle but a metal needle can also be used, provided the first 5 mL of blood are discarded in order to eliminate the metal ions from the needle. Therefore, blood samples should be collected using an intravenous catheter. After the catheter is introduced, the metal needle is withdrawn and the first five millilitres of blood are discarded to avoid possible metal contamination from the needle. A subsequent second five millilitres of blood are collected

Metals are rather stable in serum or whole blood and shipping at room temperature is allowed if it takes less than three days. The samples can be stored at 4°C for up to one week before shipping them. The samples can be stored frozen (- 20°C) for months.

4.4.2.3. Interpretation of metal ion levels

For a correct interpretation of metal ion levels, other possible sources of metal ions in blood or urine have to be excluded. Exposure to metal ions may be occupational (e.g. leather, dye, diamond industries) or environmental (air, water, soil pollution). The implantation of any metal device into the body will inevitably lead to release of metal ions either secondary to wear or to

corrosion. Intravascular stents (Ni and Cr) and dental implants (Ti) but also dental orthodontic brackets and wires (Ni, Cr, Fe, Ag, Cu, Ti) are known to release metal ions. Potential sources of metal debris from orthopaedic implants are not restricted to the bearing surfaces of MoM articulations (including knee arthroplasties and artificial lumbar discs) but may be related to interfaces with bone, cement, modular parts, screws or to delaminating metal coatings, internal fixation devices or spinal fixation devices. Intake of Co and Cr ions through medication, vitamins, or dietary substitutes is a frequent source of elevated metal ion levels. Equally, smoking and abuse of soft- or hard-drugs may lead to elevated metal ion levels. Finally, since Co and Cr are primarily excreted by the kidneys, renal impairment and insufficiency will lead to higher levels of metal ions (Brodner et al 2003) and may be considered as a contraindication for the implantation of MoM hip arthroplasties.

It is important to specifically question patients regarding possible exposure, implantation of metal components, intake of metal ions and to check the renal function in order not to misinterpret elevated ion levels.

As whole blood and serum levels cannot be used interchangeably, Smolders et al (2011) have provided a formula for conversion from serum to blood of $0.34 + [0.88 * \text{Co serum}]$ for cobalt and $0.14 + [0.58 * \text{Cr serum}]$ for chromium, with an acceptable prediction error below $\pm 1.0 \mu\text{g/L}$. They do not recommend the use of whole blood over serum measurements or vice versa.

4.4.3. Possibility for analysis of synovial fluid and periprosthetic tissue

The hip joint is the first compartment where metal particles are released. After MoM implantation it is therefore possible to identify them in the joint fluid as well as in periprosthetic tissue (Beraudi et al 2013, De Pasquale et al 2013, Langton et al 2010, Langton et al 2012, Nadu et al 2012). It is, however, more difficult to retrieve synovial fluid samples or even tissue biopsies than to draw venous blood.

De Pasquale et al (2013) performed an investigation to assess the correlation between particles in the synovial fluid and circulating Co/Cr ions in whole blood as well as serum samples of 40 patients after a mean post-operative follow-up of 4.4 years. In nearly half of the cohort no metal particles could be identified in the synovial fluid and the whole blood Co level in these patients was 0.05–4.42 $\mu\text{g/L}$. In the remaining patients, a strong positive correlation between synovial fluid Co/Cr particles and the blood metal ions could be determined. The highest correlation existed for metal particles and cobalt levels. Although the authors conclude that systemic Co and Cr levels represent the local intraarticular particle release and can therefore be used for the monitoring of wear processes, further investigations are necessary to apply these data to clinical practice.

Regarding metal deposition in periprosthetic tissue (i.e. joint capsule), characteristic histologic responses have been described (Willert et al 2005, Pandit et al 2008, Langton et al 2010, Langton et al 2012, Nadu et al 2012). According to Nadu et al (2012), the spectrum of changes seen in ARMD is distinctive. There is a "conglomerate of surface necrosis, with macrophagic response containing fine metallic debris, sometimes forming granulomas, along with an evolving ALVAL /perivascular lymphocytic infiltrate with or without germinal centres". As the amount of surface necrosis is variable, it can be difficult to distinguish the tissue response in ARMD from other chronic inflammatory arthropathies. Metal particle load in peri-articular tissue can be graded (Langton et al 2010) in order to allow correlation with the rate of volumetric wear. The current value of histologic analysis, however, must be seen in the post-hoc analysis of retrieved tissue samples after revision surgery (to confirm the diagnosis of ARMD). The knowledge concerning any association between pathologic tissue response and clinical problems, especially in early stages of local adverse reactions, is still not sufficient to enable the use of histologic grading in the analysis to decide whether a revision should be undertaken.

4.4.4. Conclusions

Various diagnostic tools are available for routine screening as well as for the investigation of symptomatic patients after MoM hip arthroplasty. In addition to clinical examination plain X-rays are the primary measure to obtain information on the implant as well as the quality of periarticular bone. Ultrasound and MARS-MRI can be helpful to detect local adverse soft tissue reactions (i.e. fluid accumulation and pseudotumours), while CT investigation is mainly used to quantify bony destruction.

Assessment of metal ion levels can be performed in whole blood, serum, urine and joint fluid. Currently, for routine purpose the analysis of Co-concentration in whole blood (or serum) is preferable. In order to assure validity and reproducibility, the adherence to standardized protocols for sample collection and analysis is mandatory. Measurements of metal particles and/or metal ions in synovial fluid and prosthetic tissue could be helpful in analysing a potential correlation between local metal particle deposition and local or systemic adverse effects. However, appropriate technologies to measure deposited (metallic) particles in tissues are still a subject of research.

4.5. Metal toxicology

4.5.1. General issues

Several different metal alloys are used in Metal-on-Metal (MoM) implants. The bearing surface itself is mostly made from CoCrMo-alloys. They may in addition contain small amounts of nickel (Ni), iron (Fe), manganese (Mn), silicon (Si). The alloys are manufactured either wrought, cast, annealed and sometimes heat-treated. They can be additionally coated with chromium-nitride (CrN), chromium-carbon-nitride (CrCN), titanium-nitride (TiN) or titanium-niobium-nitride (TiNbN). For allergy patients, coated Ti-alloys may be used as bearing articulations. The metal shell of modular cups and the stem are typically made of Ti-alloys in different compositions. In addition to Ti, these alloys may contain Al, V, Mo, Si, and Fe in varying percentages. These components are sometimes coated with hydroxyapatite. Monobloc cups are always made from CoCr-alloys. The outer surface is sometimes coated with a plasma sprayed titanium coating.

In the compound of an alloy, the specific properties of the pure elements, such as toxicity and allergenicity of cobalt, chromium and vanadium become almost insignificant; this fact is responsible for the biocompatibility of the alloys. Metallic implant materials should be as corrosion resistant as possible, but the conditions of use may render them susceptible to degradation by various pathways.

The MoM arthroplasty leads to a release of metal containing products, including a large set of forms such as metallic particles, alloys, salts, and ions which can in addition form metallo-organic compounds. These metal containing products have been found in body fluids, lymph nodes and organs.

For all metals and metal salts, bioavailability is highly dependent on the route of exposure, the solubility of the metal or metal salt in water/tissues, and particle size. The deposition of metals in the body may result in local and systemic adverse health effects. Unfortunately, analytical techniques cannot differentiate easily between these different forms of metallic compounds hampering linkage to the effects to specific compounds.

Adverse reactions to metal debris and metal ions (ARMD) are now well recognized. These reactions are manifested either as inflammatory fluid collections or as cystic or solid non-infectious soft-tissue masses around the hip or as osteolytic lesions.

The reactions can be subdivided into 2 categories. One category, called "metal reactivity," is an innate immunity response manifested as a nonspecific foreign-body reaction. This is a normal immunologic response to a large amount of metal debris, is the most common local adverse reaction, and invariably occurs with increased wear. With well-positioned, well-

functioning HRAs, they are rare, but do occur more frequently with large diameter MoM THAs as a result of enhanced taper/ trunnion wear.

A second category, called "metal allergy," is an adaptive immunity response manifested as a delayed type IV hypersensitivity, an abnormal response to a small amount of metal debris that occurs in people with a genetic allergic predisposition.

Metal toxicity has been known and studied for a long time. Therefore, most information on metal toxicity is available in Toxicology textbooks. However, this information is of limited use in the present context, since the degradation products are not adequately characterized. This is an important area for further research.

4.5.2. Conclusion

Case reports and first results of observational studies (see chapter 4.3.3.2. "systemic toxicity") indicate that toxic reactions are possible after exposure to high metal ion levels in malfunctioning MoM implants.

The application of toxicology data from either animal studies or occupational studies for evaluation of adverse effects of metals in patients with MoM hip arthroplasties is currently limited, since the degradation products are not adequately characterized. This is an important area for further research.

4.6. Clinical strategies for the management of patients with implanted MoM

Since safety concerns after the implantation of MoM implants have been raised, several health authorities and scientific societies in different countries have published recommendations for patient management (Afssaps, BHS, Dutch Orthopaedic Association, Lombardi et al 2012, MHRA, Health Products and Food Branch Inspectorate HC). Relevant recent statements are listed in the Annex.

Other relevant current comments as published by individual authors and research groups as well as recently established recommendations from an European multidisciplinary expert group, which was endorsed by the European Federation of National Associations of Orthopaedics and Traumatology (EFORT), shall be summarized in the next chapters.

4.6.1. Recent opinions and comments

Predictive value of metal ion screening

Two reviews on blood and serum ion concentrations of Cr and Co following various MoM hip arthroplasties have recently been published: Jantzen et al (2013) included 43 studies and 16 different MoM implants. They calculated average ion concentrations and range from the reported mean or median ion concentrations for the different types of bearings. The average Cr concentration ranged between 0.5 and 2.5 µg/L in blood and between 0.8 and 5.1 µg/L in serum. For Co, the range was 0.7–3.4 µg/L in blood and 0.3–7.5 µg/L in serum. Hartmann et al (2013) analyzed 104 studies with a total of 9,957 patients where measurement of metal ions in body fluids had been identified. After small-head MoM arthroplasty median Co-concentrations varied between 0.65 and 1.5 µg/L at six months and between 0.7 and 1.7 µg/L two years postoperatively. Median Co-concentrations after large-head MoM arthroplasty varied between 0.7 and 3.26 µg/L six months and between 3.77 and 5.38 µg/L two years postoperatively. After resurfacing, median serum Co-concentrations varied between 1.12 and 3.7 µg/L six months and between 0.54 and 4.28 µg/L two years postoperatively. While Jantzen et al (2013) were unable to detect any clear difference in ion concentrations between different types of implants (MoM THA and resurfacing), the latter results - as well as reported maximum

values in the study of Hartmann et al (2013) demonstrate that Co-levels were consistently higher at all postoperative assessments in patients who received large-head and resurfacing MoM arthroplasty compared to patients who received small-head MoM implants. Both studies failed, however, to detect upper acceptable limits for Cr and Co in blood.

Several authors have tried to define cut-off levels for well-functioning versus poor-functioning prostheses in the past years (Langton et al 2010, Langton et al 2011, Kwon 2010 Matthies 2012, Kwon 2011, Hart 2011, Van Der Straeten 2012). In fig. 3 a selection of cobalt cut-off-levels from various studies analyzing cohorts with "good" and "bad" functioning MoM implants is outlined. Due to the large range of levels in each of the two groups reported in all investigations, a significantly large overlap can be recognized, although the average values for 'good-functioning' implant are included in a limited range (1.5-3.5 µg/L)

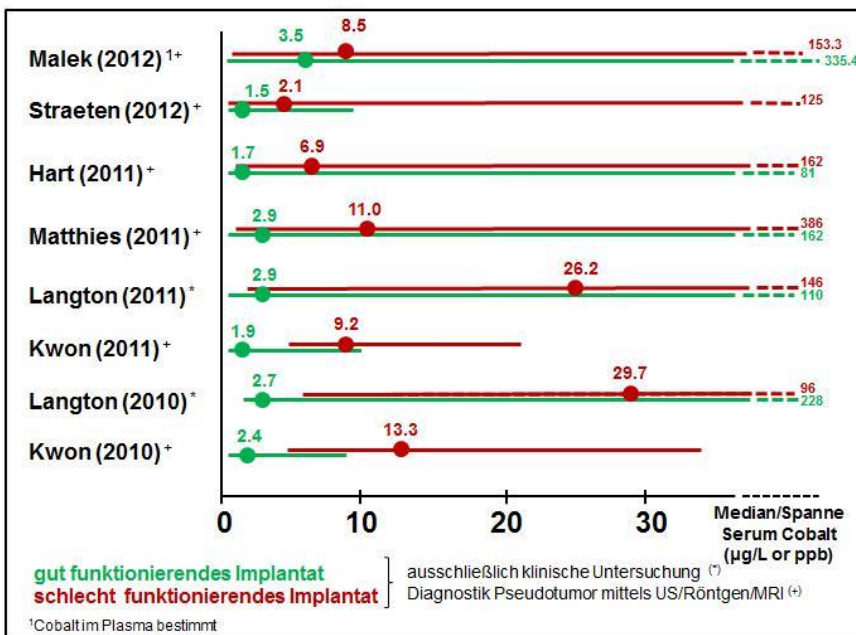


Fig. 3 Range of metal ion levels and thresholds for good (green lines) and bad (red lines) functioning MoM implants (Source: Günther et al 2013)

Based on available data, the British Medicines and Healthcare Products Regulatory Agency (MHRA) has published Medical Device Alerts in 2010 (updated in 2012), stating that a blood metal ion level >7 ppb (=µg/L) (equal to 119 nmol/L cobalt or 134.5 nmol/L chromium) indicates potential for soft tissue reaction in MoM hip arthroplasties (<http://www.mhra.gov.uk>).

Recently a study was conducted at a large HRA referral centre in Ghent, Belgium (Van der Straeten et al 2013). According to the authors, the upper acceptable levels of cobalt were at 4 µg/L for unilateral and 5µg/L for bilateral HRA. Levels above these limits had a very high probability of predicting poor function or malpositioning of the implants (specificity of 95%). These proposed levels are lower than the MHRA-levels of 7µg/L, but they are based on very strict criteria for the definition of a well-functioning HRA such as absence of clinical and radiographic findings and correct implant positioning. The high specificity and odds ratios of the proposed limits in predicting problematic HRA are concurrent with a report published by Sidiginamale et al (2013), where outer values of metal ions with poorly functioning implants were associated with high wear (they established the upper safe levels of Co in whole blood as 4.5 µg/L with 95% specificity). Levels higher than 10 µg/L had a 100% specificity of predicting clinical problems. Hart et al (2012) recommend a serum cobalt threshold level of 4.97 µg/L based on ROC-curve analyses. However, no explicit advice is given on how to treat patients above this value. Smolders et al (2013) recently pointed out that metal ion trends may be more predictive for malfunctioning MoM implants than single measurements. Although

their patient cohort is relatively small, the observation of larger metal ion increases over time in sub-optimal functioning HRA is interesting.

It is well known that exposure to very high levels of Co (>10 µg/L) significantly increases the risk of local and systemic adverse reactions. Considering this, Langton et al (2013) recommend revision surgery even in the absence of symptoms for patients with grossly elevated metal ion concentrations.

Other studies are in doubt about the predictive value of metal ion determination: Van der Weegen et al (2013) recently correlated metal ion levels with MARS MRI investigations in MoM patients as well as in a control group. They found normal metal ion levels in 80% of the MARS-MRI screened patients. Griffin et al (2012) investigated 89 MoM implants with preoperative cobalt and chromium ion levels. Using 7 µg/L as a threshold, cobalt and chromium ion levels had poor sensitivity and specificity (Co, 65% and 56%; Cr, 29% and 75%). Positive predictive values for cobalt and chromium were only 48% and 26% respectively. The authors concluded that ion levels are unreliable predictors of periarticular soft tissue damage and should not be used in isolation as surgical intervention triggers. Macnair et al (2013) also used a threshold of 7 µg/L and could show that the cobalt- as well as chromium levels in a significant proportion of their patients with MRI-documented ARMD was below this cut-off. Another recent study (Malek et al 2013) compared cobalt and chromium investigations with MARS-MRI as the reference standard for the diagnosis of ARMD and reported a 57% sensitivity and 65% specificity of cobalt or chromium serum ion analysis with a cut-off of > 7 µg/L. A lowered threshold of > 3.5 µg/L for cobalt and chromium ion levels improved the sensitivity to 86% but at the expense of specificity (27%). The authors, therefore, do not recommend metal ion analysis as a sole screening test in the surveillance of symptomatic MoM patients. In a meta-analysis of publications investigating metal ion levels after MoM THR, Hartmann et al (2013) have concluded that substantial heterogeneity in study designs, techniques and medium of metal ion assessment significantly impair the possibility to draw firm conclusions about threshold levels for the indication to surgical revision at the moment.

Predictive value of imaging studies

There is clinical consensus that plain radiographs are mandatory for routine follow-up investigations after MoM hip arthroplasty as well as for the diagnostic work-up of symptomatic patients. Radiographs underestimate, however, the prevalence of pseudotumours in MoM patients. In order to assess the presence as well as the size of soft tissue lesions (pseudotumours or fluid-filled cavities, tendon avulsions) additional ultrasound or MARS-MRI investigations are necessary. Three-dimensional estimation of periprosthetic bone cysts necessitates appropriate CT controls with metal artifact reduction.

Several investigations addressed the question of whether clinical symptoms in MoM hip arthroplasty correlate with MRI findings: Chang et al (2012) found an association between patient pain and the presence of bone marrow edema as well as abductor tendon tears, but no association between pain and the presence or size of pseudotumours. Hart et al (2012) report similar pseudotumour frequency in MRI screening of asymptomatic patients with well-functioning MoM hip arthroplasties and patients with a painful MoM hip. Other studies also confirm that in asymptomatic patients adverse tissue reactions can be detected with MRI-screening (Thomas 2013). It seems that MARS MRI is not only a helpful tool to investigate painful MoM hips, but it is also capable to detect asymptomatic soft tissue lesions in patients with clinically well-functioning implants. The presence of intra-articular fluid, synovitis or small pseudotumours, however, may not necessarily indicate the need for revision arthroplasty, as pathological findings on imaging studies do not always show a good correlation with clinical symptoms. Most authors recommend, therefore, that the need for revision procedures should be based on a combination of diagnostic tools. Van der Weegen et al (2013) present a clinical guideline for pseudotumour treatment which is mainly based on MRI severity grading, but also includes the interpretation of metal ion levels and clinical symptoms.

In conclusion, MRI and/or CT are – in addition to conventional radiographs - useful investigations to identify the cause of pain in a symptomatic hip and to support surgical planning. Further correlation of clinical and imaging data is necessary, however, to determine the natural history of periprosthetic soft-tissue lesions to guide clinical practice.

4.6.2. European multidisciplinary consensus statement on the use and monitoring of metal-on-metal bearings for THA and HRA

A multidisciplinary European panel, which was endorsed by the European Federation of National Associations of Orthopaedics and Traumatology (EFORT) developed the following recommendations (Günther et al 2013, Hannemann et al 2013).

Safety assessment of patients after implantation of MoM bearings

Due to the risks of MoM bearings, systematic follow-up is recommended for all patients and all implants. For small-head MoM THA, a systematic follow-up comparable to conventional THA is sufficient. A closer follow-up is recommended, however, for large-head MoM (annual follow-up for the life of the joint) as well as HRA. In the latter, annual follow up for the first five years is recommended according to local protocols for patients with conventional THA. If metal ion levels are normal at year one and two postoperatively, the frequency of further annual follow-up investigations may be changed to local protocols for conventional THA. In patients with risk factors such as small size HRA (<50mm femoral component), female gender, and low coverage arc, annual follow-up for the life of the joint is recommended.

All patients should undergo radiographic examination during follow-up. In case of clinical / radiographic abnormality, additional imaging (ultrasound, CT-scan, and/or MARS-MRI) is recommended. Ordinary MRI without MARS-technique is ineffective. In case of Co-values above a certain threshold (within the range of 2 to 7 µg/L;), additional imaging (e.g. ultrasound, CT-scan, and/or MARS-MRI) is recommended.

Monitoring of metal ions should be performed at the time of regular follow-up in asymptomatic patients. In all symptomatic patients additional monitoring is recommended between regular follow-up investigations. Metal ion determination of body fluids can be performed in blood, serum and urine (at present measurement of whole blood is most practicable). Cobalt should be monitored as reference substance. Ion measurement must be performed under the rules of internal/external quality control (GF-AAS and ICP-MS are considered as valid). The preferred reporting units should be micrograms/liter (=ppb). The threshold value for clinical concern is expected to be within the range of 2 to 7 µg/L (exact levels have still to be determined within this range). In increased values above the threshold, additional imaging even in asymptomatic patients is recommended. Recommendations are based on local effects; critical values for systemic effects have not yet been established for patients after MoM implantation.

Indications for revision of MoM implants for safety reasons

The appropriate management for local ARMD is based on whether or not a patient has symptoms. In asymptomatic patient, small fluid collection indicative of ARMD needs close monitoring (repeated imaging is recommended). In symptomatic patients and /or patients with progressive osteolysis, large or expanding pseudotumour, and/or progressive neck thinning, and/or Cobalt-ions above threshold level, revision may be considered.

If the metal ions levels are above threshold level at first detection but the patient is asymptomatic, the levels should be confirmed through repeated measurement in asymptomatic patients. Above a threshold of 2 to 7 µg/L (exact level still to be determined) additional imaging and closer follow-up is recommended. In case of pathological results of additional imaging and/or further significant increase of Cobalt-level, revision surgery should be discussed with the patient, as significant metal accumulation with local ARMD is to be

expected (especially in Cobalt-values $>20 \mu\text{g/L}$). In case of excessive elevation (Cobalt approximately $20 \mu\text{g/L}$ or above), because of potential osteolysis, tissue necrosis, and long-term health effects, revision surgery should also be discussed with the patient. The individual risk-benefit-ratio should always be considered before intervention.

Routine monitoring of metal ions after removal of MoM bearings is not recommended.

Appropriate communication/distribution of recommendations to patients

Before intended surgery with MoM bearing implants, every patient must be informed comprehensively and understandably in written and oral form about the benefits, risks, uncertainties, and recommended monitoring concerning MoM bearings. There should be a dialogue between the patient and the surgeon. Patients with already implanted large-head MoM THA and HRA should be informed that a higher frequency of monitoring is recommended compared to conventional MoM bearings. Risks and benefits should be expressed by patient-relevant outcomes such as morbidity, health-related Quality-of-Life, and risk of adverse effects. Absolute risk estimations are preferable to relative risk estimations. It should be highlighted that a complete (100%) prediction of positive or adverse outcomes is not possible. Uncertainties concerning both, risks and benefits, should be made explicit.

The information should allow patients to make informed decisions concerning the implantation of MoM bearings as well as to provide indication for revision in problem cases involving implanted MoM. Different stakeholder including but not necessarily limited to patient organizations, orthopedic surgeons, toxicologists, and epidemiologists should be involved in the development of the patient information. Any potential conflicts of interest of persons involved in the development of the patient information should be declared. There should be free and unrestricted access to this information and it may be disseminated in different formats, through different media, and/or through different organisations, but the information communicated through these means should be identical in content.

Appropriate communication/distribution of recommendations to surgeons and other medical disciplines

Information to surgeons should clearly and comprehensively cover the benefits, risks, uncertainties, and recommended monitoring concerning MoM bearings including product-related as well as implantation-related aspects. Communications should include the advice to assess and consider the patient's individual benefit-to-risk-ratio prior to surgery and include the recommendations as described above concerning safety assessment of patients after implantation of MoM bearings as well as indication for revision surgery. The information should be based on a systematic and comprehensive literature review and should highlight the level of evidence for any recommendation (i.e. expert opinion, single RCT, single non-RCT, meta-analysis of randomized/non-randomized studies). It should also include a declaration of potential conflicts of interest of persons involved in the development of the information. Communications should be disseminated in different formats, through different media, and/or organisations, but should be identical in content. They should also be provided to other medical disciplines (i.e. neurologists, cardiologists, oncologists, toxicologist), as patients with MoM implants may seek their advice.

4.6.3. Results of MoM revision surgery

The decision about appropriate indications for revision surgery of non well-functioning MoM implants must also take into account the results of these procedures. There is, however, only a small number of studies with appropriate design and follow-up available at the moment.

Most authors agree that the clinical results after revision of MoM implants are worse than the outcome after revision of other THA implants. The complication rates vary extensively but 2-3 years after revision, the complication rate for the studied cohorts is in the range of 8-38% for

infections, loosening, recurrence of pseudotumour and dislocation (Grammatopolous et al 2009, Steiger et al 2010, Liddle 2013, De Smet et al 2011, Munro et al 2013, Wyles et al 2013). It is difficult to compare those studies, however, as they describe different indications to revise and non-standardized surgical revision procedures. In addition, they report relatively small numbers and several types and brands of primary MoM prosthesis.

Therefore, no general consensus exists in the current literature regarding indications or the technical procedures for revision surgery. Certain trends, however, can be observed in revisions of both stemmed and resurfacing MoM hips: As to the surgical technique the general professional opinion reflects a uniform surgical approach and revision strategy including resection of all accessible reactive and necrotic tissue without endangering vital structures. In significant ARMD, one of the main issues is to end with a non MoM-articulation (if possible, CoP, CoC or MoP). Cementless acetabular cups with a modular insert and small-head articulations may allow isolated exchange of ball and insert. Monoblock metal sockets, however, need removal and insertion of a new acetabular component. In the past non well-functioning femoral components in HRA have often be revised to a stemmed large-head THR with retention of the acetabular metal cup. While Ball et al (2007) anticipated favourable result with this approach, more recent publications have demonstrated unfavourable clinical outcome of large-head THA (see chapter 4.3.1.2). Therefore this strategy is no longer appreciated and full revision including removal of the acetabular metal shell in non well-functioning HRA should be performed. With the recently increased awareness of potential trunnion problems, it is difficult to determine the adequate procedure in cases with stable fixation of the femoral component and trunnion wear. If substantial macroscopic damage can be observed, however, a complete revision of even a well fixed stem must be performed. Subtle damage may be compensated by the application of a new metal ball. If ceramic heads are to be used in combination with an already implanted stem, appropriate sleeve adapters are mandatory.

No consensus strategy exists regarding the appropriate timing of revision surgery in ARMD cases. Due to the higher complication rate in the presence of large pseudotumours and severe tissue destruction, revision should always be recommended once progression is observed. Future research, however, should determine risk factors for disease progression and adequate revision strategies.

4.6.4. Conclusions

Currently no universally accepted consensus exists on how patients with implanted MoM hip arthroplasties are to be managed. It is generally agreed that *asymptomatic* patients need regular follow-up (time intervals and screening investigations depending on the implant category as well as on the presence of pathologic findings). In patients with *symptoms*, extended investigational protocols must be applied. They should include analysis of metal ion blood levels (Co is recommended) and appropriate imaging techniques (i.e. US, CT and/or MARS-MRI in addition to plain radiographs) in order to determine the presence of local adverse reactions as well as the potential of systemic adverse reactions.

Various detailed examination protocols and treatment proposals including consensus based recommendations of an European multidisciplinary expert panel are available. They differ, however, with respect to the role of metal ion determination, imaging strategy and indication to surgical revision. It is generally accepted that low ion concentrations (Co <2µg/L) are rarely associated with significant local tissue damage and that significantly elevated ion concentrations (Co > 7µg/L) may indicate a problem with the articulation. But precise determination of threshold values for good versus bad implant function - including their relevance for decision making regarding revision surgery - necessitates further investigations. Preferably, a clear association between imaging findings and metal ion levels should be found, although local risks can vary from systemic risks, hampering such association.

4.7. Conclusions of MoM implants

4.7.1. Risk factors for MoM implants

Main risk factors for increased wear and release of metal products with subsequent development of local adverse reactions as well as potential systemic problems in all MoM implants are

- surgeon specific: inadequate positioning of components (i.e. elevated inclination and anteversion of the acetabular component leading to edge loading)
- patient specific: female gender and small femoral head diameter (resulting in low functional arc with consecutive overload) and susceptible individuals (i.e. patients with known allergic reactions to metal)
- implant specific: unfavourable tribology characteristics (i.e. low carbon content) and design features (i.e. low functional arc) of individual implant types; large-head THA with trunnion wear due to increased friction

4.7.2. Benefit factors for MoM implants

- There are no polyethylene particles in pure MoM bearings that may cause inflammation and subsequent osteolysis
- MoM bearings produce less volumetric wear compared to conventional polyethylene
- There is a reduced risk of fracture in MoM bearings compared to ceramics
- MoM is currently the only material available for HRA
- Large-head MoM THA (head diameter of 36mm and larger) as well as HRA have a reduced risk of dislocation compared to small-headsmall-head THA (< 36 mm head size). In large-head THA, range of motion increases with the head size (only up to 40mm).
- MoM HRA allows more preservation of bone stock on the femoral side when compared to conventional THA
- MoM HRA may be associated with superior short- to mid-term clinical outcomes (i.e. hip function, health-related Quality-of-Life) in comparison to conventional stemmed THA in well selected subgroups of young and active male patients

4.7.3. Follow-up of MoM implants and induced adverse effects

MoM implants release metal particles which can induce adverse effects locally (periarticular bone and soft tissue damage) as well as systemically (toxicity, carcinogenicity, teratogenicity). The current database on the incidence of these potential problems in patients with MoM hip arthroplasty is incomplete and all risks can basically also apply to patients with conventional THA. Therefore providing specific and evidence-based guidelines on the follow-up of MoM patients is currently not possible. General recommendations, however, can be given which are based on recent statements of European national institutions as well as on the opinion of a multidisciplinary consensus approach:

Due to the risks of MoM bearings systematic follow-up is recommended for all patients and all implants. For small-head MoM THA a systematic follow-up comparable to conventional THA is sufficient. A closer follow-up is recommended, however, for large-head MoM (annual follow-up for the life of the joint) as well as HRA. In the latter, annual follow up for at least the first five years is recommended, then it may be changed to local protocols for patients with conventional THA (if metal ion levels are not significantly elevated). In HRA-patients with special risk factors (i.e. small component size, female gender, low coverage arc) annual follow-up for the life of the joint is recommended. All patients should undergo clinical as well as radiographic examination during follow-up. Metal ion determination is currently recommended

for large-head MoM THA on a routine basis and for HRA patients at least in the first postoperative years (thereafter it may depend on their clinical performance). In case of clinical and/or radiographic abnormality as well as in case of significantly elevated metal ion levels additional imaging (ultrasound, CT-scan, and/or MARS-MRI) is recommended. A metal ion concentration within the range of 2 to 7 µg/L cobalt-concentration may currently serve as the threshold value for the necessity of further investigations. Metal ion determination for screening purposes should be performed in whole blood. Cobalt can serve as the reference substance.

It must be outlined that these recommendations are based on potential local adverse effects of MoM arthroplasties, as critical values for systemic effects have not yet been established.

Concerning follow-up, it is also noted that:

- Manufacturers should organise a post-market follow up of their materials on the market;
- Patients need more clarification on the reimbursement of diagnostic procedures following MoM arthroplasty. In various European countries there are different health system regulations or even a lack of generally accepted rules for the payment of proposed follow-up investigations in patients with MoM implants

4.7.4. Gaps in knowledge

The main gaps in knowledge where further research is necessary in order to solve relevant questions are the following:

1. Clinical relevance and significance of metal ion determination in body fluids
 - comparative value of blood and urine as screening tools
 - effects of long-term exposure to metal ion blood concentrations between 2 and 7 µg/L
 - reproducibility of metal ion measurements among different labs.
 - levels of metal ions after the implantation of any other kind of artificial implant (i.e. knee arthroplasty, spine implants and osteosynthesis devices)
2. Incidence and clinical relevance of local and systemic adverse effects:
 - frequency of ARMD in different categories of MoM implants
 - frequency of potential organ toxicity, carcinogenicity and teratogenicity after implantation of MoM arthroplasties (as well as metal containing conventional arthroplasties)
3. Pathomechanisms of local and systemic distribution of metal particles, ions and metallo-organic compounds
 - characterization of wear products from joint articulations and taper interfaces
 - influence of relevant parameters on wear and corrosion of taper connections
 - correlations between the presence of wear / corrosion at taper connections and the presence / extent of ARMD
 - mechanisms creating particles / ions / metallo-organic compounds or aggregates in bearings of different diameter
 - systemic effects of an internal exposure to metal ions (i.e. Co, Cr) in contrast to external (industrial and environmental) exposure
 - potential impact of additional metal ions (i.e. titanium).
4. other relevant issues:

- prevalence of local and systemic adverse effects of MoM in joint registries
- interaction between wear and corrosion of MoM interfaces
- appropriate pre-clinical testing methods for metal implants (including biomechanic testing as well as in-vitro models) to investigate local and systemic consequences of metal particle release

4.8. Research recommendations

4.8.1 Pre-clinical research

It is necessary, to improve our knowledge on the particle release and especially the interaction of wear and corrosion from different categories (small-head and large-head MoM THA, HRA) as well as parts of implants (i.e. stem, taper junction, bearing surfaces). In addition it is mandatory to understand more of the different regulatory mechanisms in implant marketing and introduction into clinical practice.

Suggestions for research:

- 1) Investigate the influence of relevant parameters on wear and corrosion of taper connections (taper size, diameter and length), material, texture, head diameter, joint articulation friction, assembly forces and direction. Wear products from taper interfaces and joint articulation should be characterised, if possible
- 2) Determine the mechanisms creating particles / ions / metallo-organic compounds or aggregates in large ($\geq 36\text{mm}$) and small ($<36\text{mm}$) MoM bearings functioning under ideal and suboptimal conditions. The distribution of nano-particles should be determined
- 3) Determine the potential impact of additional metal ions (i.e. titanium)
- 4) Investigate the interaction between wear and corrosion of MoM interfaces and develop appropriate pre-clinical testing methods; means (by design or metallurgy) to avoid synergistic corrosion effects should be identified
- 5) Establish in-vitro models to investigate local and systemic consequences of metal debris (i.e. 3-d scaffolds)
- 6) Perform further studies of the biology of the exposure using experimental animal systems. It would be important to test the relative effects of exposure to particles, ions and metal complexes trying wherever possible to recreate the modes of wear that are seen in vivo (including corrosion and impingement).
- 7) Perform studies on improved metal to tissue interfaces
- 8) Study the effects of different regulatory requirements in different countries on the introduction of new implants on the market

4.8.2 Clinical research

Currently the main gaps of knowledge concern the frequency as well as the clinical relevance (including pathomechanism) of adverse local as well as systemic effects of an internal exposure to metal ions. The most important and clinically relevant questions to answer are

- 1) What is the biological reaction to periprosthetic local as well systemic exposure to metal particles and ions?
- 2) What are the systemic effects of different metal products in different organs?

- 3) Is there an increased risk of cancer from all types of metal implants and especially MoM implants?
- 4) When and how should revisions of MoM patients be performed?
- 5) Do non-surgical alternatives exist?

Suggestions for research:

- 1) Perform studies in patient samples at sites where cancer risk has been highlighted (bladder, kidney skin, bone marrow, blood, prostate). Test whether there are potential mutagenic or even precancerous changes in cells at possible risk of metal exposure (i.e. melanocytes). Perform correlations of these changes with metal accumulation at these sites to test whether there might be any relation with exposure.
- 2) Continue to follow up patients using modern epidemiology, wherever possible subdividing patients according to the levels of their exposures, type of implant, performance of the implant e.g. revision surgery and whether the patients have specific diseases which might act as confounding variables. It is necessary to determine the true incidence as well as clinical relevance of ARMD in all categories of MoM implants.
- 3) Determine metal ion levels after the implantation of any kind of artificial implant (i.e. knee arthroplasty, spine implants and osteosynthesis devices) and to investigate associations with clinical symptoms.
- 4) Upon revision of MoM implants correlations between the presence of wear / corrosion at taper connections and the presence / extent of adverse local tissue reactions (i.e. necrosis, pseudotumour) should be examined systematically.
- 5) Correlate the changes found in preclinical in-vitro studies and animal models with those found in clinical investigations (i.e. imaging, body fluid analysis) and autopsy.
- 6) Establish an "Autopsy bank" with post-mortem samples of different tissues (brain, heart, lung, kidney, liver, spleen, lymph node, skin) as well as urine and blood at autopsy.
- 7) Perform comparative tests to investigate urine as a screening tool.
- 8) Identify issues concerning the reproducibility of metal ion measurements among different labs.

4.8.3 Post-market studies

It is necessary to establish a traceability system in order to follow-up potential adverse events in MoM patients. The infrastructure of partly-existing hip arthroplasty registries in different European countries could be used for this purpose.

Suggestions for research:

- 1) Establish Hip Arthroplasty Registers with better documentation of reasons for revision
- 2) Health service research regarding appropriateness of regular follow-up investigations in MoM-patients including reimbursement issues in order to establish risk-benefit calculations

5. OPINION

A summary of the scientific rationale can be found in section 1. Executive Summary.

Terms of reference and answers

Q1: To determine the short, medium and long term local and systemic health effects caused by metal particles, metal ions, metallo-organic compounds resulting from the implanted medical device and if possible to provide indications on limit values for the metals in any forms.

Metal-on-Metal (MoM) hip arthroplasty leads to a release of metal products (e.g. particles and ions) which can in addition form metallo-organic compounds in the body. These products can subsequently be deposited in draining lymph nodes and internal organs. This may result in local and systemic adverse health effects. However, it is not possible to determine whether these are due to metal particles, ions or metallo-organic compounds released from the implants.

Local tissue reactions: The local responses can be described as consisting of a broad clinical spectrum ranging from small asymptomatic tissue lesions to severe destruction of bone and soft tissues. These lesions are designated by different terminologies such as: metallosis, ALVAL (aseptic lymphocytic vasculitis associated lesion), pseudotumours and ARMD (adverse reactions to metal debris). These local responses can be diagnosed at any time after surgery (short-, medium- and long- term). Based on follow-up studies, a threshold value for clinical concern is expected to be within the range of 2 to 7 µg/L (exact levels have still to be determined within this range).

Systemic adverse responses: The application of toxicology data from either animal studies or occupational studies for evaluation of adverse effects of metals in patients with MoM hip arthroplasties is currently limited since the degradation products are not adequately characterized. Therefore, the observations in various animal studies cannot be extrapolated to the internal exposure as seen by release of metals from MoM implants. There are some specific concerns related to the possible systemic exposure to cobalt and/or chromium after MoM-hip arthroplasty such as systemic organ toxicity, carcinogenicity and teratogenicity. Although some papers indicate systemic organ effects and an increase in tumor rate, the evidence is insufficient and needs further confirmation. Currently no distinction between short, medium and long term systemic effects is possible. Regarding teratogenicity, potential transplacental passage of metal ions has been demonstrated in the absence of any teratogenic effect up to now.

Two different categories of MoM arthroplasties have to be differentiated: Total Hip Arthroplasty THA with either small (head diameter < 36 mm) or large-heads (head diameter > = 36 mm), and Resurfacing Hip Arthroplasty (HR, always large-head diameter). The described adverse health effects apply to all types of these MoM hip arthroplasties. MoM arthroplasty with large diameters (resurfacing and especially large-head MoM THA) show the highest incidence of local reactions. For systemic health effects, no association with the type of implant or diameter has been established up to now. Local as well as systemic adverse effects can also occur with other types of metallic implants (e.g. plates, screws).

Critical values for systemic effects have not yet been established for patients after MoM implantation, mainly due to the lack of data.

Q2: To advise on the predictive value of metal ions in body fluids, clinical strategies and other aspects needed to ensure the safety of implanted patients. Criteria that should inform the medical decision with respect to the implanted patient should be identified where possible.

Based on the current information, no exact values of critical metal ions thresholds can be given for clinical decision-making regarding clinical follow-up. The SCENIHR decided to adopt the strategy as outlined in the European Consensus Statement. This strategy includes recommendations on technical issues (e.g. metal ion determination for screening purposes should be performed in whole blood) and determination of critical threshold ranges (e.g. for Co a range of 2 to 7 µg/L Co whole blood was defined).

One of these recommendations concerns systematic follow up for all patients and all implants due to the risks of MoM bearings. For small-head MoM THA a systematic follow-up comparable to conventional THA is sufficient. A closer follow-up is recommended, however, for large-head MoM (annual follow-up for the life of the joint) as well as HRA. For the latter, annual follow-up for at least the first five years is recommended, then it may be changed to local protocols for patients with conventional THA (if metal ion levels are not significantly elevated). Another recommendation refers to HRA-patients with special risk factors (i.e. small component size, female gender, low coverage arc) for whom annual follow-up for the lifetime of the joint is recommended. However, all patients should undergo clinical as well as radiographic examination during follow-up. Metal ion determination is currently recommended for large-head MoM THA on a routine basis and for HRA patients at least in the first postoperative years (thereafter it may depend on their clinical performance In case of clinical and/or radiographic abnormality, as well as in case of significantly elevated metal ion levels (i.e. metal ion values above a certain threshold, which is currently within the range of 2 to 7 µg/L Cobalt-concentration), additional imaging (ultrasound, CT-scan, and/or MARS-MRI) is recommended. Metal ion determination for screening purposes should be performed in whole blood. Cobalt can serve as reference substance.

Importantly, these recommendations are based on potential local adverse effects of MoM arthroplasties, because critical values for systemic effects have not yet been established.

Q3: To identify criteria regarding the safety and safe use of MoM implants used in arthroplasty, paying special attention to design and patient groups.

The application of MoM hip arthroplasty should be carefully considered on a case-by-case basis, due to the potential adverse effects of released metal, especially in certain subgroups of patients.

All types of MoM implants are contra-indicated for example in females of childbearing age and in patients who are allergic to relevant metals. MoM HRA should not be performed in females with small femoral head size. In carefully selected young and active male patients with large femoral head size and favourable head-neck-ratio, however, HRA can be an alternative to conventional THA.

The choice of the type of implant should be based on a detailed case-by-case evaluation taking into account all risks and benefits. The patient should be informed about the specific adverse effects related to MoM implants and should be followed up rigorously.

Finally, the procedure – the placing – should be performed by very experienced surgeons to reduce the risk of incorrect positioning to a minimum.

The MoM experience indicates that the stepwise introduction of new implants types, even if similar to those in use in the market, should be accompanied by proper pre-clinical and clinical studies. The regulatory approval by the Notified Bodies in Europe should not be based on the acceptance of minimal design changes.

Q4: Where relevant to identify needs for further research.

For additional safety evaluation, data on internal exposure in animal toxicity studies is necessary for comparison with exposures occurring in patients who received MoM arthroplasty.

Further research is necessary to clarify which components of metallic debris are responsible for the local and/or systemic adverse reactions.

Further research is necessary to investigate the contribution of the bearing and the taper interface to the production of metallic debris. The taper interface should also be the focus of further research including other bearing articulations.

Prospective studies should be made into the relationship between patients metal levels and clinical outcome. This research should include standardised reliable methodology for metal determination.

Research into local and systemic reactions in post-mortem samples including determination of metals and their various combinations.

Research into the possible role of other metals than Co and Cr such as Ti and V, in view of the inconsistency in relationship between the clinical outcome and Co/Cr metal ion levels. In addition, research is needed to replace the metals by other "hard", stable and low hazardous materials (i.e ceramic implants).

Determine the incidence and prevalence of adverse local and systemic health effects in patients with MoM hip arthroplasties by setting up mandatory national registries providing the required data. This requirement should be applied to all permanent implants.

6. MINORITY OPINION

None

7. LIST OF ABBREVIATIONS

Ag:	Silver
Al:	Aluminium
ALVAL:	Aseptic lymphocytic vasculitis associated lesion
ARMD:	Adverse reactions to metal debris
CoC:	Ceramic-on-Ceramic
CoP:	Ceramic-on-Polyethylene
Co:	Cobalt
Cr:	Chromium
CrCN:	Chromium carbon nitride
CrN:	Chromium nitride
CT:	Computed Tomography
Cu:	Copper
Fe:	Iron
HRA:	Hip resurfacing arthroplasty
MARS-MRI:	Metal Artifact Reduction Sequence - Magnetic Resonance Imaging
Mo:	Molybdenum
Mn:	Manganese
MoM:	Metal-on-Metal
MoP:	Metal-on-Polyethylene
MRI:	Magnetic Resonance Imaging
Ni:	Nickel
QoL:	Quality-of-Life
Si:	Silicon
THA:	Total hip arthroplasty
Ti:	Titanium
TiN:	titanium nitride
TiNbN	titanium niobium nitride
US:	Ultrasound
µg/L:	Microgram per liter
V:	Vanadium

8. REFERENCES

- Afssaps, Agence française de sécurité sanitaire des produits de santé. Prothèses de hanche ASR du fabricant DePuy rappelées en juillet 2010. Recommandations de l'Afssaps. 2012. <http://ansm.sante.fr/content/download/39685/518877/version/3/file/pi-120229-protheses-DePuy.pdf> (checked November 2012).
- Amstutz HC, Le Duff MJ, Campbell PA, Gruen TA, Wisk LE (2010) Clinical and radiographic results of Metal-on-Metal hip resurfacing with a minimum ten-year follow-up. *J Bone Joint Surg Am* 92(16):2663-71
- Anderson H, Toms AP, Cahir JG, Goodwin RW, Wimhurst J, Nolan JF. Grading the severity of soft tissue changes associated with Metal-on-Metal hip replacements: reliability of an MR grading system. *Skeletal Radiol.* 2011 Mar;40(3):303-7. Epub 2010 Jul 25.
- Aqil A, Drabu R, Bergmann JH, Masjedi M, Manning V, Andrews B, Muirhead-Allwood SK, Cobb JP. The gait of patients with one resurfacing and one replacement hip: a single blinded controlled study. *Int Orthop.* 2013 May;37(5):795-801. doi: 10.1007/s00264-013-1819-3. Epub 2013 Feb 27.
- Australian Orthopaedic Association National Joint Replacement Registry. Annual report 2011. Published October 2011 and since then available at: www.dmac.adelaide.edu.au/aoanjrr/publications.jsp. Accessed October 15, 2011.
- Australian Orthopaedic Association National Joint Replacement Registry (2012) Hip and Knee Arthroplasty - Annual Report 2012. <https://aoanjrr.dmac.adelaide.edu.au/documents/10180/60142/Annual%20Report%202012?version=1.2&t=1355186837517>
- Baan, R. A. Carcinogenic hazards from inhaled carbon black, titanium dioxide, and talc not containing asbestos or asbestiform fibers: recent evaluations by an IARC Monographs Working Group. *Inhal. Toxicol.* 2007, 19 Suppl 1, 213-228.
- Ball ST, Le Duff MJ, Amstutz HC (2007) Early results of conversion of a failed femoral component in hip resurfacing arthroplasty. *J Bone Joint Surg Am* 89(4):735-41
- Baur W, Honle W, Willert HG, Schuh A (2005) [Pathological findings in tissue surrounding revised metal/metal articulations]. *Orthopade* 34(3):225-233
- Benedetti MG, Berti L, Frizziero A, Ferrarese D, Giannini S. Functional recovery after hip resurfacing and rehabilitation. *J Sport Rehabil.* 2012 May;21(2):167-74.
- Beraudi A, Montesi M, Stea S, Sudanese A, Apostoli P, Toni A. Detection of cobalt in synovial fluid from metal-on-metal hip prosthesis: correlation with the ionic haematic level. *Biomarkers* 2013: Early Online 1-7. doi:10.3109/1354750X.2013.846413
- Bermudez, E.; Mangum, J. B.; Asgharian, B.; Wong, B. A.; Reverdy, E. E.; Janszen, D. B.; Hext, P. M.; Warheit, D. B.; Everitt, J. I. Long-term pulmonary responses of three laboratory rodent species to subchronic inhalation of pigmentary titanium dioxide particles. *Toxicological Sciences* 2002, 70 (1), 86-97.
- Bermudez, E.; Mangum, J. B.; Wong, B. A.; Asgharian, B.; Hext, P. M.; Warheit, D. B.; Everitt, J. I. Pulmonary responses of mice, rats, and hamsters to subchronic inhalation of ultrafine titanium dioxide particles. *Toxicol. Sci.* 2004, 77 (2), 347-357.
- BHS. BHS statements on large diameter metal on metal bearing total hip replacements. 2012. [http://www.britishhipsociety.com/uploaded/BHS MOM THR.pdf](http://www.britishhipsociety.com/uploaded/BHS%20MOM%20THR.pdf) (checked November 2012).
- Bisschop R, Boomsma MF, Van Raay JJAM, Tiebosch ATMG, Maas M, Gerritsma CLE. High Prevalence of Pseudotumours in Patients with a Birmingham Hip Resurfacing Prosthesis. A Prospective Cohort Study of One Hundred and Twenty-nine Patients. *J Bone Joint Surg Am.* 2013;95:1554-6

- Bjorgul K, Novicoff WN, Andersen ST, Ahlund OR, Bunes A, Wiig M, Brevig K. High rate of revision and a high incidence of radiolucent lines around Metasul metal-on-metal total hip replacements: results from a randomised controlled trial of three bearings after seven years. *Bone Joint J.* 2013 Jul;95-B(7):881-6.
- Boffetta, P.; Gaborieau, V.; Nadon, L.; Parent, M. E.; Weiderpass, E.; Siemiatycki, J. Exposure to titanium dioxide and risk of lung cancer in a population-based study from Montreal. *Scandinavian Journal of Work Environment & Health* 2001, 27 (4), 227-232.
- Boffetta, P.; Soutar, A.; Cherrie, J. W.; Granath, F.; Andersen, A.; Anttila, A.; Blettner, M.; Gaborieau, V.; Klug, S. J.; Langard, S.; Luce, D.; Merletti, F.; Miller, B.; Mirabelli, D.; Pukkala, E.; Adami, H. O.; Weiderpass, E. Mortality among workers employed in the titanium dioxide production industry in Europe. *Cancer Causes Control* 2004, 15 (7), 697-706.
- Bolland BJ, Culliford DJ, Langton DJ, Millington JP, Arden NK, Latham JM (2011) High failure rates with a large-diameter hybrid Metal-on-Metal total hip replacement: clinical, radiological and retrieval analysis. *J Bone Joint Surg Br* 93(5):608-615
- Boomsma MF, H B Ettema and C Van Der Straeten, The hip resurfacing handbook: A practical guide to the use and management of modern hip resurfacings. PART 2 CLINICAL FOLLOW-UP The use of Computerized Tomography (CT) to evaluate hip resurfacing. Edited by K De Smet, ANCA Clinic, Belgium, P Campbell, UCLA, USA and C Van Der Straeten, Consultant, Belgium <http://www.woodheadpublishing.com/en/book.aspx?bookID=2090>
- Bosker BH, Ettema HB, Boomsma MF, Kollen BJ, Maas M, Verheyen CC (2012) High incidence of pseudotumour formation after large-diameter Metal-on-Metal total hip replacement: a prospective cohort study. *J Bone Joint Surg Br* 94(6):755-61
- Brewster DH, Stockton DL, Reekie A, Ashcroft GP, Howie CR, Porter DE, Black RJ. Risk of cancer following primary total hip replacement or primary resurfacing arthroplasty of the hip: a retrospective cohort study in Scotland. *Br J Cancer.* 2013 May 14;108(9):1883-90. doi: 10.1038/bjc.2013.129. Epub 2013 Apr 2
- Brodner W, Bitzan P, Meisinger V, Kaider A, Gottsauner-Wolf F, Kotz R. Serum cobalt levels after metal-on-metal total hip arthroplasty. *J Bone Joint Surg Am.* 2003;85:2168-73.
- Brodner W, Grohs JG, Bancher-Todesca D, Dorotka R, Meisinger V, Gottsauner-Wolf F, Kotz R (2004) Does the placenta inhibit the passage of chromium and cobalt after Metal-on-Metal total hip arthroplasty? *J Arthroplasty* 19(8 Suppl 3):102-106
- Canadian Arthroplasty Society. The Canadian Arthroplasty Society's experience with hip resurfacing arthroplasty. An analysis of 2773 hips. *Bone Joint J.* 2013 Aug;95-B(8):1045-51
- Chang EY, McAnally JL, Van Horne JR, Statum S, Wolfson T, Gamst A, Chung CB. Metal-on-metal total hip arthroplasty: do symptoms correlate with MR imaging findings? *Radiology.* 2012 Dec;265(3):848-57. doi: 10.1148/radiol.12120852. Epub 2012 Oct 9
- Chen Z, Pandit H, Taylor A, Gill H, Murray D, Ostlere S. Metal-on-metal hip resurfacings—a radiological perspective. *Eur Radiol.* 2011 Mar;21(3):485-91. Epub 2010 Sep 15.
- Chen Z, Wang Z, Wang Q, Cui W, Liu F, Fan W. Changes in Early Serum Metal Ion Levels and Impact on Liver, Kidney, and Immune Markers Following Metal-on-Metal Total Hip Arthroplasty. *J Arthroplasty.* 2013 Aug 27. pii: S0883-5403(13)00549-4. doi: 10.1016/j.arth.2013.07.031. [Epub ahead of print]
- Chen, J. L.; Fayerweather, W. E. Epidemiologic-Study of Workers Exposed to Titanium-Dioxide. *Journal of Occupational and Environmental Medicine* 1988, 30 (12), 937-942.
- Consensus statement "Current Evidence on the Management of Metal-on-Metal Bearings". http://www.efort.org/communications/pdf/2012_05_10_MoM_Consensus_statement.pdf
- Cousen PJ, Gawkrödger DJ. Metal allergy and second-generation metal-on-metal arthroplasties. *Contact Dermatitis.* 2012 Feb;66(2):55-62. doi: 10.1111/j.1600-0536.2011.01970.x. Epub 2011 Sep 29.

- Cuckler JM, Moore KD, Lombardi AV, Jr., McPherson E, Emerson R (2004) Large versus small femoral heads in Metal-on-Metal total hip arthroplasty. *J Arthroplasty* 19(8 Suppl 3):41-4
- Daniel J, Holland J, Quigley L, Sprague S, Bhandari M (2012) Pseudotumours associated with total hip arthroplasty. *J Bone Joint Surg Am.* 94(1): 86-93
- Daniel J, Ziaee H, Kamali A, Pradhan C, Band T, McMinn DJ (2010) Ten-year results of a double-heat-treated Metal-on-Metal hip resurfacing. *J Bone Joint Surg Br* 92(1):20-7
- Daniel J, Ziaee H, Pradhan C, McMinn DJ. Six-year results of a prospective study of metal ion levels in young patients with Metal-on-Metal hip resurfacings. *J Bone Joint Surg Br* 2009;91:176-179.
- Daniel J, Ziaee H, Pradhan C, Pynsent PB, McMinn DJ (2010) Renal clearance of cobalt in relation to the use of Metal-on-Metal bearings in hip arthroplasty. *J Bone Joint Surg Am* 92(4):840-845
- De Haan R, Campbell PA, Su EP, De Smet KA. Revision of metal-on-metal resurfacing arthroplasty of the hip: the influence of malpositioning of the components, *J Bone Joint Surg Br.* 2008;90(9):1158-63
- De Haan R, Pattyn C, Gill HS, Murray DW, Campbell PA, De Smet K. Correlation between inclination of the acetabular component and metal ion levels in Metal-on-Metal hip resurfacing replacement. *J Bone Joint Surg Br.* 2008;90:1291-1297.
- De Pasquale D, Stea S, Squarzone S, Bordini B, Amabile M, Catalani S, Apostoli P, Toni A. Metal-on-metal hip prostheses: Correlation between debris in the synovial fluid and levels of cobalt and chromium ions in the bloodstream. *Int Orthopaedics* 2013; On-line first (Oct) 10.1007/s00264-013-2137-
- De Smet K, De Haan R, Calistri A, Campbell PA, Ebramzadeh E, Pattyn C, Gill HS. Metal ion measurement as a diagnostic tool to identify problems with Metal-on-Metal hip resurfacing. *J Bone Joint Surg Am.* 2008;90(Suppl 4):202-208.
- De Smet K, Van Der Straeten C, Van Orsouw M, Doubi R, Backers K, Grammatopoulos G. Revisions of Metal-on-Metal Hip Resurfacing: Lessons Learned and Improved Outcome. *Orthopedic Clinics of North America* 42, April 2011, 259-269.
- De Smet KA, Van Der Straeten C. Revisions of Metal-on-Metal hip resurfacing: causes, treatment options and improved outcome. *Minerva Ortopedica e Traumatologica* 2012; 63:111-23.
- deSouza RM, Wallace D, Costa ML, Krikler SJ (2012) Transplacental passage of metal ions in women with hip resurfacing: no teratogenic effects observed. *Hip Int* 22(1):96-99
- Desy NM, Bergeron SG, Petit A, Huk OL, Antoniou J. Surgical variables influence metal ion levels after hip resurfacing. *Clin Orthop Relat Res* 2011;469:1635-1641.
- Duggan PJ, Burke CJ, Saha S, Moonim M, George M, Desai A, Houghton R. Current literature and imaging techniques of aseptic lymphocyte-dominated vasculitis-associated lesions (ALVAL). *Clin Radiol.* 2013 Nov;68(11):1089-96. doi: 10.1016/j.crad.2013.04.017. Epub 2013 Aug 6.
- Dunstan E, Ladon D, Whittingham-Jones P, Carrington R, Briggs TW (2008) Chromosomal aberrations in the peripheral blood of patients with Metal-on-Metal hip bearings. *J Bone Joint Surg Am* 90(3):517-522
- Dutch Orthopaedic Association. The use of Metal-on-Metal hip replacements: More strict advice to NOV members, 17January 2012. http://www.orthopeden.org/uploads/UT/Eh/UTEhC1OA_0-mRSJTfROfA/Advice-NOV-on-the-use-of-MoM-hip-replacements-17-01-2012.pdf (checked November 2012).
- Engh CA, Jr., Ho H, Engh CA (2010) Metal-on-metal hip arthroplasty: does early clinical outcome justify the chance of an adverse local tissue reaction? *Clin Orthop Relat Res* 468(2):406-12

Estey MP, Diamandidis E, Van Der Straeten C, Hart A, Tower S, Moyer T, Cobalt and Chromium Measurement in Patients with Metal Hip Prostheses. *Clin Chem*. 2012 Oct 31. [Epub ahead of print] ID# CLINCHEM/2012/193037:

Eswaramoorthy V, Moonot P, Kalairajah Y, Biant LC, Field RE (2008) The Metasul Metal-on-Metal articulation in primary total hip replacement: clinical and radiological results at ten years. *J Bone Joint Surg Br* 90(10):1278-1283

Food and Drug Administration. FDA 522 guidance document. Available at: www.fda.gov/downloads/MedicalDevices/DeviceRegulationandGuidance/GuidanceDocuments/ucm072564.pdf. Accessed August 16, 2011.

Fryzek, J. P.; Chadda, B.; Marano, D.; White, K.; Schweitzer, S.; McLaughlin, J. K.; Blot, W. J. A cohort mortality study among titanium dioxide manufacturing workers in the United States. *J. Occup. Environ. Med.* 2003, 45 (4), 400-409.

Garabrant, D. H.; Fine, L. J.; Oliver, C.; Bernstein, L.; Peters, J. M. Abnormalities of pulmonary function and pleural disease among titanium metal production workers. *Scand. J. Work Environ. Health* 1987, 13 (1), 47-51.

Garbuz DS, Tanzer M, Greidanus NV, Masri BA, Duncan CP. The John Charnley Award: Metal-on-metal hip resurfacing versus large-diameter head Metal-on-Metal total hip arthroplasty: a randomized clinical trial. *Clin Orthop Relat Res*. 2010;468: 318–325.

Garbuz DS, Hargreaves BA, Duncan CP, Masri BA, Wilson DR, Forster BB. . The John Charnley Award: Diagnostic Accuracy of MRI Versus Ultrasound for Detecting s in Asymptomatic Metal-on-Metal THA. *Clin Orthop Relat Res*. 2013 Jul 19. [Epub ahead of print]

Gill HS, Grammatopoulos G, Adshead S, Tsiologiannis E, Tsiridis E., Molecular and immune toxicity of CoCr nanoparticles in MoM hip arthroplasty, *Trends Mol Med*. 2012 Mar;18(3):145-55

Glyn-Jones S, Pandit H, Kwon YM, Doll H, Gill HS, Murray DW. Risk factors for inflammatory pseudotumour formation following hip resurfacing. *J Bone Joint Surg [Br]* 2009;91-B:1566-74.

Grammatopolous G, Pandit H, Kwon YM, Gundle R, McLardy-Smith P, Beard DJ, Murray DW, Gill HS., Hip resurfacings revised for inflammatory pseudotumour have a poor outcome, *J Bone Joint Surg Br*. 2009;91(8):1019-24.

Griffin WL, Fehring TK, Kudrna JC, Schmidt RH, Christie MJ, Odum SM, Denny AC. Are metal ion levels a useful trigger for surgical intervention? *J Arthroplasty*. 2012 Sep;27(8 Suppl):32-6

Griffin WL, Nanson CJ, Springer BD, Fehring TK. Reduced articular surface of one-piece cups: a cause of runaway wear and early failure. *Clin Orthop Relat Res*. 2010;468:2328–2332.

Gruber FW, Bock A, Trattng S, Lintner F, Ritschl P (2007) Cystic lesion of the groin due to metallosis: a rare long-term complication of Metal-on-Metal total hip arthroplasty. *J Arthroplasty* 22(6):923-927

Grubl A, Marker M, Brodner W, Giurea A, Heinze G, Meisinger V, Zehetgruber H, Kotz R (2007) Long-term follow-up of Metal-on-Metal total hip replacement. *J Orthop Res* 25(7):841-848

Günther KP, Schmitt J, Campbell P, Delaunay CP, Drexler H, Ettema HB, García-Cimbrello E, Hannemann F, Hartmann A, Huberti H, Knahr K, Kunze J, Langton DJ, Lauer W, Learmonth I, Lohmann CH, Lützner J, Morlock M, Seidler A, Wimmer MA, Zagra L. Consensus statement "Current evidence on the management of metal-on-metal bearings" - April 16, 2012. *Hip Int*. 2013 Feb 21;23(1):2-5. doi: 10.5301/HIP.2013.10754.

Günther KP, Lützner J, Hannemann F, Schmitt J, Kirschner S, Goronzy J, Stiehler M, Lohmann C, Hartmann A. Update on metal-on-metal hip joints. *Orthopade*. 2013 May;42(5):373-87; quiz 388-9. doi: 10.1007/s00132-013-2100-6. German

Haddad FS, Thakrar RR, Hart AJ, Skinner JA, Nargol AV, Nolan JF, Gill HS, Murray DW, Blom AW, Case CP. Metal-on-metal bearings: the evidence so far. *J Bone Joint Surg Br*. 2011; 93:572–579.

- Hannemann F, Hartmann, A Schmitt J, Lützner J, Seidler A, Campbell P, Delaunay CP, Drexler H, Ettema HB, García-Cimbrelo E, Huberti H, Knahr K, Kunze J, Langton DJ, Lauer W, Learmonth I, Lohmann CH, Morlock M, Wimmer MA, Zagra L, Günther KP. European multidisciplinary consensus statement on the use and monitoring of metal-on-metal bearings for total hip replacement and hip resurfacing. *Orthopaedics & Traumatology: Surgery & Research* (2013)
- Hart AJ, Sabah SA, Bandi AS, Maggiore P, Tarassoli P. Sensitivity and specificity of blood cobalt and chromium metal ions for predicting failure of MoM hip replacement. *JBJS Br* 2011; 93-B: 1308-1313.
- Hart AJ, Skinner JA, Henckel J, Sampson B, Gordon F. Insufficient acetabular version increases blood metal ion levels after Metal-on-Metal hip resurfacing. *Clin Orthop Relat Res* 2011;469:2590-2597.
- Hart AJ, Satchithananda K, Liddle AD, Sabah SA, McRobbie D, Henckel J, Cobb JP, Skinner JA, Mitchell AW. Pseudotumors in association with well-functioning metal-on-metal hip prostheses: a case control study using three-dimensional computed tomography and magnetic resonance imaging. *J Bone Joint Surg Am* 2012;94:317e25
- Hartmann A, Hannemann F, Lützner J, Seidler A, Drexler H, Günther KP, Schmitt J. Metal ion concentrations in body fluids after implantation of hip replacements with metal-on-metal bearing--systematic review of clinical and epidemiological studies. *PLoS One*. 2013;8(8):e70359. doi: 10.1371/journal.pone.0070359. eCollection 2013
- Hartmann A, Lutzner J, Kirschner S, Witzleb WC, Gunther KP (2012) Do Survival Rate and Serum Ion Concentrations 10 Years After Metal-on-Metal Hip Resurfacing Provide Evidence for Continued Use? *Clin Orthop Relat Res* 470(11):3118-26
- Health Products and Food Branch Inspectorate HC. Important safety information regarding metal-on-metal hip implant surgery. April 11, 2012. http://www.hc-sc.gc.ca/dhp-mps/alt_formats/pdf/medeff/advisories-avis/prof/2012/metal_implant_hpc-cps-eng.pdf (checked November 2012).
- Heinrich, U.; Fuhst, R.; Rittinghausen, S.; Creutzenberg, O.; Bellmann, B.; Koch, W.; Levsen, K. Chronic Inhalation Exposure of Wistar Rats and 2 Different Strains of Mice to Diesel-Engine Exhaust, Carbon-Black, and Titanium-Dioxide. *Inhalation Toxicology* 1995, 7 (4), 533-556.
- Heisel C, Streich N, Krachler M, Jakubowitz E, Kretzer JP. Characterization of the running-in period in total hip resurfacing arthroplasty: an in vivo and in vitro metal ion analysis. *J Bone Joint Surg Am*. 2008;90:125-133.
- Hext, P. M.; Tomenson, J. A.; Thompson, P. Titanium dioxide: inhalation toxicology and epidemiology. *Ann. Occup. Hyg.* 2005, 49 (6), 461-472.
- Hur CI, Yoon TR, Cho SG, Song EK, Seon JK (2008) Serum ion level after Metal-on-Metal THA in patients with renal failure. *Clin Orthop Relat Res* 466(3):696-699
- Jantzen C, Jørgensen HL, Duus BR, Sparring SL, Lauritzen JB. Chromium and cobalt ion concentrations in blood and serum following various types of metal-on-metal hip arthroplasties: a literature overview. *Acta Orthop.* 2013 Jun;84(3):229-36. doi: 10.3109/17453674.2013.792034. Epub 2013 Apr 18
- Johnson AJ, Woon RP, Le Duff MJ, Amstutz HC. Childhood development after maternal metal-on-metal hip resurfacing. *Hip Int.* 2013 Mar-Apr;23(2):181-6. doi: 10.5301/HIP.2013.10731. Epub 2013 Feb 12.
- Keegan GM, Learmonth ID, Case CP (2007) Orthopaedic metals and their potential toxicity in the arthroplasty patient: A review of current knowledge and future strategies. *J Bone Joint Surg Br* 89(5):567-573
- Korovessis P, Petsinis G, Repanti M, Repantis T (2006) Metallosis after contemporary Metal-on-Metal total hip arthroplasty. Five to nine-year follow-up. *J Bone Joint Surg Am* 88(6):1183-1191

Kwon YM, Ostlere SJ, McLardy-Smith P, Athanasou NA, Gill HS, Murray DW. 'Asymptomatic' pseudotumors after metal-on-metal hip resurfacing arthroplasty: prevalence and metal ion study. *J Arthroplasty*. 2011;26:511-518.

Kwon YM, Thomas P, Summer B, Pandit H, Taylor A, Beard D, Murray DW, Gill HS (2010) Lymphocyte proliferation responses in patients with pseudotumors following Metal-on-Metal hip resurfacing arthroplasty. *J Orthop Res* 28(4):444-450

Langton DJ, Jameson SS, Joyce TJ, Gandhi JN, Sidaginamale R, Merredy P, Lord J, Nargol AV. Accelerating failure rate of the ASR total hip replacement. *J Bone Joint Surg Br* 2011;93:1011-1016.

Langton DJ, Jameson SS, Joyce TJ, Hallab NJ, Natsu S, Nargol AV (2010) Early failure of Metal-on-Metal bearings in hip resurfacing and large-diameter total hip replacement: A consequence of excess wear. *J Bone Joint Surg Br* 92(1):38-46

Langton DJ, Joyce TJ, Jameson SS, Lord J, Van OM, Holland JP, Nargol AV, De Smet KA. Adverse reaction to metal debris following hip resurfacing: the influence of component type, orientation and volumetric wear. *J Bone Joint Surg Br* 2011; 93(2):164-171

Langton DJ, Sprowson AP, Joyce TJ, Reed M, Carlisle I, Partington P, Nargol AV. Blood metal ion concentrations after hip resurfacing arthroplasty: a comparative study of articular surface replacement and Birmingham Hip Resurfacing arthroplasties. *J Bone Joint Surg Br*. 2009;91:1287-1295.

Langton DJ, Sidaginamale RP, Joyce TJ, Natsu S, Blain P, Jefferson RD, Rushton S, Nargol AV. The clinical implications of elevated blood metal ion concentrations in asymptomatic patients with MoM hip resurfacings: a cohort study. *BMJ Open*. 2013 Mar 12;3(3).

Learmonth, I. D., Gheduzzi, S., Vail, T. P.: Clinical experience with Metal-on-Metal total joint replacements: indications and results. *Proc.Inst.Mech.Eng H*. 220, 229-237,(2006).

Lee, K. P.; Trochimowicz, H. J.; Reinhardt, C. F. Pulmonary response of rats exposed to titanium dioxide (TiO₂) by inhalation for two years. *Toxicol. Appl. Pharmacol*. 1985, 79 (2), 179-192.

Leikin JB, Karydes HC, Whiteley PM, Wills BK, Cumpston KL, Jacobs JJ. Outpatient toxicology clinic experience of patients with hip implants. *Clin Toxicol (Phila)*. 2013 May;51(4):230-6. doi:

Li, J.; Li, Q.; Xu, J.; Li, J.; Cai, X.; Liu, R.; Li, Y.; Ma, J.; Li, W. Comparative study on the acute pulmonary toxicity induced by 3 and 20 nm TiO₂ primary particles in mice. *Environmental Toxicology and Pharmacology* 2007, 24 (3), 239-244.

Liddle AD, Satchithananda K, Henckel J, Sabah SA, Vipulendran KV, Lewis A, Skinner JA, Mitchell AW, Hart AJ. Revision of metal-on-metal hip arthroplasty in a tertiary center: a prospective study of 39 hips with between 1 and 4 years of follow-up. *Acta Orthop*. 2013;84(3):237-45

Lingard EA, Muthumayandi K, Holland JP. Comparison of patient-reported outcomes between hip resurfacing and total hip replacement. *J Bone Joint Surg [Br]* 2009;91-B:1550-4.

Lombardi AV Jr, Barrack RL, Berend KR, Cuckler JM, Jacobs JJ, Mont MA, Schmalzried TP. The Hip Society: algorithmic approach to diagnosis and management of metal-on-metal arthroplasty. *J Bone Joint Surg Br*. 2012 Nov;94(11 Suppl A):14-8

Mac Donald SJ, Brodner W, Jacobs JJ. A consensus paper on metal ions in Metal-on-Metal hip arthroplasties. *J Arthroplasty*. 2004;19(Suppl 3):12-16.

Machado C, Appelbe A, Wood R. Arthroprosthetic cobaltism and cardiomyopathy. *Heart Lung Circ*. 2012 Nov;21(11):759-60. doi: 10.1016/j.hlc.2012.03.013. Epub 2012 Apr 18.

Macnair RD, Wynn-Jones H, Wimhurst JA, Toms A, Cahir J. Metal ion levels not sufficient as a screening measure for adverse reactions in metal-on-metal hip arthroplasties. *J Arthroplasty*. 2013 Jan;28(1):78-83. doi: 10.1016/j.arth.2012.05.029. Epub 2012 Jul 6.

Malek IA, King A, Sharma H, Malek S, Lyons K, Jones S, John A. The sensitivity, specificity and predictive values of raised plasma metal ion levels in the diagnosis of adverse reaction to

metal debris in symptomatic patients with a metal-on-metal arthroplasty of the hip. *J Bone Joint Surg Br.* 2012 Aug;94(8):1045-50. doi: 10.1302/0301-620X.94B8.27626.

Makela KT, Visuri T, Pulkkinen P, Eskelinen A, Remes V, Virolainen P, Junnula M, Pukkala E (2012) Risk of cancer with Metal-on-Metal hip replacements: population based study. *BMJ* 345:e4646

Marker M, Grubl A, Riedl O, Heinze G, Pohanka E, Kotz R (2008) Metal-on-metal hip implants: do they impair renal function in the long-term? A 10-year follow-up study. *Arch Orthop Trauma Surg* 128(9):915-919

Matthies AK, Skinner JA, Osmani H, Henckel J, Hart AJ (2012) Pseudotumors are common in well-positioned low-wearing Metal-on-Metal hips. *Clin Orthop Relat Res* 470(7):1895-1906

McBryde CW, Theivendran K, Thomas A, Treacy R, Pynsent PB. The influence of head size and sex on the outcome of Birmingham Hip Resurfacing. *J Bone Joint Surg Am.* 2010;92:105-112.

Medical device alert of the Medicines and Healthcare products Regulatory Agency on all Metal-on-Metal (MoM) hip replacements. MDA/2010/033. Issued April 22, 2010. Available at: www.mhra.gov.uk/Publications/Safetywarnings/MedicalDeviceAlerts/CON079157. Accessed April 22, 2010.

Medicines and Healthcare Products Regulatory Agency (2012) Medical Device Alert: Metal-on-metal (MoM) hip replacements. MDA/2012/008. <http://www.mhra.gov.uk/home/groups/dts-bs/documents/medicaldevicealert/con143787.pdf>

Meyer H, Mueller T, Goldau G, Chamaon K, Ruetschi M, Lohmann CH (2012) Corrosion at the Cone/Taper Interface Leads to Failure of Large-diameter Metal-on-metal Total Hip Arthroplasties. *Clin Orthop Relat Res* 470(11):3101-3108

MHRA. Medical Device Alert. All metal-on-metal (MoM) hip replacements. 25 June 2012 <http://www.mhra.gov.uk/home/groups/dts-bs/documents/medicaldevicealert/con155767.pdf> (checked November 2012).

Milosev I, Trebse R, Kovac S, Cor A, Pisot V (2006) Survivorship and retrieval analysis of Sikomet Metal-on-Metal total hip replacements at a mean of seven years. *J Bone Joint Surg Am* 88(6):1173-1182

Mokka J, Junnula M, Seppänen M, Virolainen P, Pölönen T, Vahlberg T, Mattila K, Tuominen EK, Rantakokko J, Aärimaa V, Kukkonen J, Mäkelä KT. Adverse reaction to metal debris after ReCap-M2A-Magnum large-diameter-head metal-on-metal total hip arthroplasty. *Acta Orthop.* 2013 Oct 31. [Epub ahead of print]

Mokka J, Mäkelä KT, Virolainen P, Remes V, Pulkkinen P, Eskelinen A. Cementless Total Hip Arthroplasty with Large Diameter Metal-on-Metal Heads: Short-Term Survivorship of 8059 Hips from the Finnish Arthroplasty Register. *Scand J Surg.* 2013 Jun 1;102(2):117-23

Mont MA, Seyler TM, Ragland PS, Starr R, Erhart J, Bhav A. Gait analysis of patients with resurfacing hip arthroplasty compared with hip osteoarthritis and standard total hip arthroplasty. *J Arthroplasty.* 2007 Jan;22(1):100-8.

Mueller LA, Schmidt R, Ehrmann C, Nowak TE, Kress A, Forst R, Pfander D. Modes of periacetabular load transfer to cortical and cancellous bone after cemented versus uncemented total hip arthroplasty: a prospective study using computed tomography-assisted osteodensitometry. *J Orthop Res.* 2009 Feb;27(2):176-82. doi: 10.1002/jor.20742

Muhle, H.; Bellmann, B.; Creutzenberg, O.; Koch, W.; Dasenbrock, C.; Ernst, H.; Mohr, U.; Morrow, P.; Mermelstein, R. Pulmonary response to toner, TiO₂ and crystalline silica upon chronic inhalation exposure in Syrian golden hamsters. *Inhalation Toxicology* 1998, 10 (7), 699-729.

Munro JT, Masri BA, Duncan CP, Garbuz DS., High Complication Rate After Revision of Large-head Metal-on-metal Total Hip Arthroplasty., *Clin Orthop Relat Res.* 2013 Apr 10. [Epub ahead of print]

- Nawabi DH, Hayter CL, Su EP, Koff MF, Perino G, Gold SL, Koch KM, Potter HG. Magnetic resonance imaging findings in symptomatic versus asymptomatic subjects following metal-on-metal hip resurfacing arthroplasty. *J Bone Joint Surg Am*. 2013 May 15;95(10):895-902. doi: 10.2106/JBJS.K.01476.
- National Institute for Clinical Excellence. Guidance on the selection of prosthesis for primary total hip replacement (TA2). Available at <http://www.nice.org.uk> Accessed October 8, 2011
- National Joint Registry Annual report 2010.
<http://www.njrcentre.org.uk/njrcentre/Home/tabid/36/Default.aspx>
- National Joint Registry. Annual report 2011.
<http://www.njrcentre.org.uk/njrcentre/Home/tabid/36/Default.aspx>
- National Joint Registry. Annual report 2012;
<http://www.njrcentre.org.uk/njrcentre/Home/tabid/36/Default.aspx>
- National Joint Registry. Annual report 2013.
<http://www.njrcentre.org.uk/njrcentre/Home/tabid/36/Default.aspx>
- Natu S, Sidaginamale RP, Gandhi J, Langton DJ, Nargol AV (2012) Adverse reactions to metal debris: histopathological features of periprosthetic soft tissue reactions seen in association with failed metal on metal arthroplasties. *J Clin Pathol* 65(5): 409-418
- Nunley RM, Della Valle CJ, Barrack RL. Is patient selection important for hip resurfacing? *Clin Orthop Relat Res*. 2009;467: 56-65.
- Oldenburg M, Wegner R, Baur X. Severe cobalt intoxication due to prosthesis wear in repeated total hip arthroplasty. *J Arthroplasty*. 2009 Aug;24(5):825.e15-20. doi: 10.1016/j.arth.2008.07.017. Epub 2008 Oct 2
- Onega T, Baron J, MacKenzie T. Cancer after total joint arthroplasty: a meta-analysis. *Cancer Epidemiol Biomarkers Prev*. 2006; 15:1532-7
- Ostlere S. How to image Metal-on-Metal prostheses and their complications. *AJR* 197:558-567
- Pandit H, Glyn-Jones S, McLardy-Smith P, Gundle R, Whitwell D, Gibbons CL, Ostlere S, Athanasou N, Gill HS, Murray DW. Pseudotumours associated with metal-on-metal hip resurfacings. *J Bone Joint Surg Br*. 2008;90:847-851.
- Park YS, Moon YW, Lim SJ, Yang JM, Ahn G, Choi YL (2005) Early osteolysis following second-generation Metal-on-Metal hip replacement. *J Bone Joint Surg Am* 87(7):1515-1521
- Pastides PS, Dodd M, Sarraf KM, Willis-Owen CA. Trunnionosis: A pain in the neck. *World J Orthop* 2013 October 18; 4(4): 161-166
- Petersen MK, Andersen NT, Mogensen P, Voight M, Søballe K. Gait analysis after total hip replacement with hip resurfacing implant or Mallory-head Exeter prosthesis: a randomised controlled trial. *Int Orthop*. 2011 May;35(5):667-74. doi: 10.1007/s00264-010-1040-6. Epub 2010 May 16.
- Pott, F.; Roller, M. Carcinogenicity study with nineteen granular dusts in rats. *Eur. J. Oncol*. 2005, 10, 249-281.
- Prentice JR, Clark MJ, Hoggard N, Morton AC, Tooth C, Paley MN, Stockley I, Hadjivassiliou M, Wilkinson JM. Metal-on-metal hip prostheses and systemic health: a cross-sectional association study 8 years after implantation. *PLoS One*. 2013 Jun 10;8(6):e66186
- Rahman, L., M. Hall-Craggs, and S. K. Muirhead-Allwood. "Radiology of the resurfaced hip." *Skeletal Radiol*. 40.7 (2011): 819-30.
- Rajpura A, Porter ML, Gambhir AK, Freemont AJ, Board TN, Clinical experience of revision of metal on metal hip arthroplasty for aseptic lymphocyte dominated vasculitis associated lesions (ALVAL), *Hip Int* 2010;21(1):43-51
- Ramanakumar, A. V.; Parent, M. E.; Latreille, B.; Siemiatycki, J. Risk of lung cancer following exposure to carbon black, titanium dioxide and talc: results from two case-control studies in Montreal. *Int. J. Cancer* 2008, 122 (1), 183-189.

Renwick, L. C.; Brown, D.; Clouter, A.; Donaldson, K. Increased inflammation and altered macrophage chemotactic responses caused by two ultrafine particle types. *Occup. Environ. Med.* 2004, 61 (5), 442-447.

Repantis T, Vitsas V, Korovessis P. Poor mid-term survival of the low-carbide metal-on-metal Zweymüller-plus total hip arthroplasty system: a concise follow-up, at a minimum of ten years, of a previous report. *J Bone Joint Surg Am.* 2013 Mar 20;95(6):e331-4. doi: 10.2106/JBJS.L.00031.

RIPO Register, <https://ripo.cineca.it>, Annual Report 2012

Sehatzadeh S, Kaulback K, Levin L.. Metal-on-metal hip resurfacing arthroplasty: an analysis of safety and revision rates. *Ont Health Technol Assess Ser.* 2012;12(19):1-63. Epub 2012 Aug 1.

Shimmin AJ, Barre JV. Comparison of functional results of hip resurfacing and total hip replacement: a review of the literature. *Orthop Clin N Am* (2011); 42:143-151

Shrader MW, Bhowmik-Stoker M, Jacofsky MC, Jacofsky DJ. Gait and stair function in total and resurfacing hip arthroplasty: a pilot study. *Clin Orthop Relat Res.* 2009 Jun;467(6):1476-84

Siddiqui IA, Sabah SA, Satchithananda K, Lim AK, Henckel J, Skinner JA, Hart AJ. Cross-sectional imaging of the metal-on-metal hip prosthesis: the London ultrasound protocol. *Clin Radiol.* 2013 Aug;68(8):e472-8. doi: 10.1016/j.crad.2013.02.003. Epub 2013 May 17.

Sidiginamale RP, Joyce TJ, Lord JK, Jefferson R, Blain PG, Nargol AV, Langton DJ. Blood metal ion testing is an effective screening tool to identify poorly performing metal-on-metal bearing surfaces. *Bone Joint Res.* 2013 May 16;2(5):84-95

Siemiatycki, J.; Dewar, R.; Nadon, L.; Gerin, M. Occupational risk factors for bladder cancer: results from a case-control study in Montreal, Quebec, Canada. *Am. J Epidemiol.* 1994, 140 (12), 1061-1080.

Sikes CV, Lai LP, Schreiber M, Mont MA, Jinnah RH, Seyler TM (2008) Instability after total hip arthroplasty: treatment with large femoral heads vs constrained liners. *J Arthroplasty* 23(7 Suppl):59-63

Smith AJ, Dieppe P, Porter M, Blom AW; National Joint Registry of England and Wales. Risk of cancer in first seven years after metal-on-metal hip replacement compared with other bearings and general population: linkage study between the National Joint Registry of England and Wales and hospital episode statistics. *BMJ.* 2012 Apr 3;344:e2383. doi: 10.1136/bmj.e2383.

Smolders JMH, Bisseling P, Hol A, Van Der Straeten C, Schreurs BW, van Susante JLC. Metal ion interpretation in resurfacing versus conventional hip arthroplasty and in whole blood versus serum. How should we interpret metal ion data? *Hip Int.* 2011;21:587-595.

Smolders JM, Hol A, van Susante JL. Metal ion trend may be more predictive for malfunctioning metal-on-metal implants than a single measurement. *Hip Int.* 2013 Oct 28;23(5):434-40

Sotos JG, Tower SS. Systemic disease after hip replacement: aeromedical implications of arthroprosthetic cobaltism. *Aviat Space Environ Med.* 2013 Mar;84(3):242-5.

Steiger de RN, Miller LN, Prosser GH, Graves SE, Davidson DC, Stanford TE. Poor outcome of revised resurfacing hip arthroplasty. 397 cases from the Australian joint replacement registry. *Acta Orthop.* 2010;81(1):72-76

Thomas MS, Wimhurst JA, Nolan JF, Toms AP. Imaging Metal-on-Metal Hip Replacements: the Norwich Experience. *HSS J.* 2013 Oct;9(3):247-256. Epub 2013 Aug 24.

Toms AP, Marshall TJ, Cahir J, Darrah C, Nolan J, Donell ST, Barker T, Tucker JK. MRI of early symptomatic metal-on-metal total hip arthroplasty: a retrospective review of radiological findings in 20 hips. *Clin Radiol.* 2008 Jan;63(1):49-58. Epub 2007 Oct 24.

Tower SS. Arthroprosthetic cobaltism: neurological and cardiac manifestations in two patients with Metal-on-Metal arthroplasty: a case report. *J Bone Joint Surg Am.* 2010;92:2847-2851.

Treacy RB, McBryde CW, Shears E, Pynsent PB (2011) Birmingham hip resurfacing: a minimum follow-up of ten years. *J Bone Joint Surg Br* 93(1):27-33

Van Der Straeten C, Grammatopoulos G, Gill HS, Calistri A, Campbell P, De Smet KA. The 2012 Otto Aufranc Award: The interpretation of Metal Ion Levels in Unilateral and Bilateral Hip Resurfacing. *Clinical Orthopedics and Related Research Vol 471, Issue 2 (2013): 377-85.*

Van Der Straeten C, Metal ions from Metal-on-Metal Hip Arthroplasties. *Orthopädie im Profil*, 8. Jahrgang. April 2012, 20-21

Van Der Straeten C, Murray D. Interpretation and Use of Data from Arthroplasty Registers. *Orthopädie im Profil*, 7. Jahrgang. April 2011

Van Der Straeten C. Researchers set safe upper limit metal ion levels for Metal-on-Metal hip resurfacings. *Orthopedics Today*. July 2012

Van der Weegen H, Hoekstra HJ, Sijbesma T, Bos E, Schemitsch EH, Poolman RW. Survival of Metal-on-Metal hip resurfacing arthroplasty. A systematic review of the literature. *J Bone Joint Surg [Br]* 2011;93-B:298-306.

van der Weegen W, Sijbesma T, Hoekstra HJ, Brakel K, Pilot P, Nelissen RG. Treatment of Pseudotumors After Metal-on-Metal Hip Resurfacing Based on Magnetic Resonance Imaging, Metal Ion Levels and Symptoms. *J Arthroplasty*. 2013 Jul 18. pii: S0883-5403(13)00434-8. doi: 10.1016/j.arth.2013.06.021. [Epub ahead of print]

van der Weegen W, Smolders JM, Sijbesma T, Hoekstra HJ, Brakel K, van Susante JL. High incidence of pseudotumours after hip resurfacing even in low risk patients; results from an intensified MRI screening protocol. *Hip Int*. 2013 May-Jun;23(3):243-9. doi: 10.5301/hipint.5000004. Epub 2012 Dec 11.

van Lingen CP, Ettema HB, Timmer JR, de Jong G, Verheyen CC. Clinical manifestations in ten patients with asymptomatic metal-on-metal hip arthroplasty with very high cobalt levels. *Hip Int*. 2013 Oct 28;23(5):441-4

Van Quickenborne D, De Smet KA, Van Der Straeten C. Gehoorverlies bij een bilaterale heupresurfacing. *Tijdschrift voor Geneeskunde* November 2012.

Vendittoli PA, Amzica T, Roy AG, Lusignan D, Girard J, Lavigne M (2011) Metal Ion release with large-diameter Metal-on-Metal hip arthroplasty. *J Arthroplasty* 26(2):282-288

Vendittoli PA, Ganapathi, Roy AG, Lusignan D, Lavigne M. A comparison of clinical results of hip resurfacing arthroplasty and 28 mm metal on metal total hip arthroplasty: a randomised trial with 3-6 years follow-up. *Hip Int* 2010; 20 (01): 1-13

Vendittoli PA, Mottard S, Roy AG, Dupont C, Lavigne M: Chromium and cobalt ion release following the Durom high carbon content, forged Metal-on-Metal surface replacement of the hip. *J Bone Joint Surg Br* 2007;89:441-448

Visuri T, Borg H, Pulkkinen P, Paavolainen P, Pukkala E (2010) A retrospective comparative study of mortality and causes of death among patients with Metal-on-Metal and metal-on-polyethylene total hip prostheses in primary osteoarthritis after a long-term follow-up. *BMC Musculoskelet Disord* 11:78

Visuri T, Pukkala E, Pulkkinen P, Paavolainen P (2003) Decreased cancer risk in patients who have been operated on with total hip and knee arthroplasty for primary osteoarthritis: a meta-analysis of 6 Nordic cohorts with 73 000 patients. *Acta Orthop Scand* 74(3):351-360

Visuri T, Pulkkinen P, Paavolainen P, Pukkala E. Cancer risk is not increased after conventional hip arthroplasty. *Acta Orthop*. 2010 Feb;81(1):77-81. doi: 10.3109/17453671003667150

Visuri TI, Pukkala E, Pulkkinen P, Paavolainen P. Cancer incidence and causes of death among total hip replacement patients: a review based on Nordic cohorts with a special emphasis on metal-on-metal bearings. *Proc Inst Mech Eng H*. 2006 Feb;220(2):399-407.

Wagner P, Olsson H, Lidgren L, Robertsson O, Ranstam J (2011) Increased cancer risks among arthroplasty patients: 30 year follow-up of the Swedish Knee Arthroplasty Register. *Eur J Cancer* 47(7):1061-1071

- Warheit, D. B.; Webb, T. R.; Reed, K. L.; Frerichs, S.; Sayes, C. M. Pulmonary toxicity study in rats with three forms of ultrafine-TiO₂ particles: differential responses related to surface properties. *Toxicology* 2007, 230 (1), 90-104.
- Warheit, D. B.; Webb, T. R.; Sayes, C. M.; Colvin, V. L.; Reed, K. L. Pulmonary instillation studies with nanoscale TiO₂ rods and dots in rats: toxicity is not dependent upon particle size and surface area. *Toxicol. Sci.* 2006, 91 (1), 227-236.
- Wiley KF, Ding K, Stoner JA, Teague DC, Yousuf KM. Incidence of pseudotumor and acute lymphocytic vasculitis associated lesion (ALVAL) reactions in metal-on-metal hip articulations: a meta-analysis. *J Arthroplasty*. 2013 Aug;28(7):1238-45. doi: 10.1016/j.arth.2013.03.027. Epub 2013 May 6.
- Willert HG, Buchhorn GH, Fayyazi A, Flury R, Windler M, Koster G, Lohmann CH (2005) Metal-on-metal bearings and hypersensitivity in patients with artificial hip joints. A clinical and histomorphological study. *J Bone Joint Surg Am* 87(1):28-36
- Willert HG, Buchhorn GH, Semlitsch M (1993) Particle disease due to wear of metal alloys. Findings from retrieval studies. In: *Biological, Material and Mechanical considerations of Joint Replacement*. Ed. Morrey BF, Raven Press Ltd., New York. pp129-146.
- Willert HG, Semlitsch M (1977) Reactions of the articular capsule to wear products of artificial joint prostheses. *J Biomed Mater Res* 11(2):157-164
- Williams DH, Greidanus NV, Masri BA, Duncan CP, Garbuz DS (2011) Prevalence of pseudotumor in asymptomatic patients after Metal-on-Metal hip arthroplasty. *J Bone Joint Surg Am* 93(23):2164-2171
- Wyles CC, Van Demark RE 3rd, Sierra RJ, Trousdale RT. High Rate of Infection After Aseptic Revision of Failed Metal-on-Metal Total Hip Arthroplasty. *Clin Orthop Relat Res*. 2013 Jul 12. [Epub ahead of print]
- Yang J, Shen B, Zhou Z, Pei F, Kang P (2011) Changes in cobalt and chromium levels after Metal-on-Metal hip resurfacing in young, active Chinese patients. *J Arthroplasty* 26(1):65-70
- Zagra L, Anasetti F, Bianchi L, Licari V, Giacometti Ceroni R. No Difference in Gait Recovery After THA With Different Head Diameters: A Prospective Randomized Study. *Clin Orthop Relat Res*. 2013
- Zeng Y, Feng W. Metal allergy in patients with total hip replacement: a review. *J Int Med Res*. 2013 Apr;41(2):247-52. doi: 10.1177/0300060513476583. Epub 2013 Feb 22.
- Zenz P, Stiehl JB, Knechtel H, Titzer-Hochmaier G, Schwagerl W (2009) Ten-year follow-up of the non-porous Allofit cementless acetabular component. *J Bone Joint Surg Br* 91(11):1443-1447
- Ziaee H, Daniel J, Datta AK, Blunt S, McMinn DJ (2007) Transplacental transfer of cobalt and chromium in patients with Metal-on-Metal hip arthroplasty: a controlled study. *J Bone Joint Surg Br* 89(3):301-305
- Zywiell MG, Brandt JM, Overgaard CB, Cheung AC, Turgeon TR, Syed KA. Fatal cardiomyopathy after revision total hip replacement for fracture of a ceramic liner. *Bone Joint J*. 2013 Jan;95-B(1):31-7. doi: 10.1302/0301-620X.95B1.30060.

Appendix 1: Detailed description of Metal-on-Metal implants

1.1. Composition of Metal-on-Metal implants

Several different metal alloys are used in Metal-on-Metal (MoM) implants. The bearing surface itself is mostly made from CoCrMo-alloys. They contain Chromium 26.5–30 %, Molybdenum 4.5–7.0%, Carbon 0.05–0.35%, Nickel <1%, Iron <1%, Manganese <1%, and Silicon <1%. Low carbon alloys contain around 0.05% Carbon, high carbon alloys around 0.20%. The exact composition of the alloys is specified in several international standards, which are summarized in ISO-21534. The alloys are manufactured either wrought, cast, annealed and sometimes heat-treated. They can be additionally coated with Chromium-Nitride (CrN), Chromium-Carbon-Nitride (CrCN), Titanium-Nitride (TiN) or Titanium-Niobium-Nitride (TiNbN). For allergy patients, also coated Ti-alloys are used as bearing articulations.

The metal shell of modular cups and the stem are typically made of Ti-alloys in different compositions. In addition to Ti, these alloys may contain, for example, Al, V, Mo, Si, and Fe in varying percentages. These components are sometimes coated with hydroxyapatite (HA) with the aim for a better bone in- or on-growth.

Monobloc cups are always made from CoCr-alloys. The outer surface is sometimes coated with a Plasma sprayed Titanium coating for the aim of better bone in- or on-growth.

1.2. Types of Metal-on-Metal implants

The first generation of Metal-on-Metal (MoM) hip prostheses is attributed to Philip Wiles in 1938. In the five decades after this innovation, several surgeons (Haboush, McKee, Lord, Ring, Huggler, Müller) adopted MoM bearing couples, but none of these designs was really successful in a high percentage of patients.

Two different design categories of MoM bearing articulations have been used more or less successfully since 1998, the start of the second generation (tighter manufacturing tolerances, better alloys), of MoM implants for total hip arthroplasty:

(1) Modular MoM

(a) Small-head THA: Modular metal head on a hip stem with a modular metal insert in a metal socket with a head diameter of less than 36 mm (Fig. 1)

(b) Large-head THA: Modular metal head on a hip stem with a metal cup, with a head diameter of 36 mm or more (Fig. 2). The metal cup could either be:

(b1) Modular

(b2) Monobloc

(2) Resurfacing (HRA): Metal resurfacing head with a monobloc metal cup (Fig. 3)

Examples of MoM hip implants are presented in Figure 1. The choice of the components is not related to the problems observed with certain Metal-on-Metal hip bearing articulations. Sizes are only examples and represent typical measures.




Figure 1: Contemporary designs of Metal-on-Metal hip joint articulations. They can be grouped into two different categories with subgroups: Category 1a: A&E&I, Category 1b1: B&F&I; Category 1b2: C&G&I; Category 2: D&H. (Source: M.Morlock)

In detail, the components are:

- (A) Metal socket with a modular metal insert in a plastic liner (diameter 28mm). The outside of the socket is made of Ti-alloy whereas the bearing surface is made from CoCr-alloy
- (B) Metal socket (Ti-alloy) with a modular metal insert made from CoCr-alloy (diameter 36mm)
- (C) Monobloc metal cup made of CoCr-alloy coated with TiNbN (diameter 42mm)
- (D) Monobloc metal cup made of CoCr-alloy (diameter 54mm)
- (E) Modular metal head made of CoCr-alloy (diameter 28mm)
- (F) Modular metal head made of CoCr-alloy (diameter 36mm)
- (G) Modular metal head made of CoCr-alloy coated with TiNbN (diameter 42mm)
- (H) Monobloc resurfacing head made of CoCr-alloy (diameter 54mm)
- (I) Modular uncemented hip stem made of Ti-alloy.

Category 1a – Small-head modular MoM

In 1998, the time of the second generation MoM bearings started (Metasul™, Sulzer, Switzerland). This design with heads of 28mm and 32mm diameter achieved similar or better clinical success as other bearing materials and is still used (Fig. 2). Newer Category 1 MoM designs are quite similar but omit the plastic (polyethylene) sandwich. Category 1 designs are typically used in conjunction with a modular uncemented hip stem and a modular uncemented hip socket both made from Ti-alloys.




Figure 2: Components of contemporary Category 1a MoM bearing articulations (Source: M.Morlock):

- (A) Backside of an uncemented hip socket with porous titanium surface for bone on- or ingrowth and screw holes for additional fixation
- (B) Frontside of the same socket with taper for fixation of the bearing insert
- (C) Metal CoCr-alloy bearing insert for a metal head with a diameter of 32mm
- (D) Metal CoCr-alloy head with a diameter of 32mm.

Category 1b - Large-head modular MoM

The use of modular metal heads with 36mm diameter and larger is rather recent. If the head diameter is getting too large, modular cups are not possible anymore and monobloc metal cups are required. These are the same cups as used with resurfacing (category 3).

Category 1b1 Large-head MoM with modular metal cup

These designs are similar to category 1a designs with exception of the larger diameter. The most common diameters range between 36 and 44mm (Fig 3).



Figure 3: The two articulating components of contemporary Category 1b1 MoM bearing articulations with a diameter of 36mm. The CoCr-alloy metal cup liner has a thinner wall thickness as the 32mm diameter liner shown in Figure 2 and such fits in the same uncemented hip socket. (Source: M.Morlock)

Category 1b2 Large-head MoM with monobloc cup

This is a rather new philosophy and part of the third generation (engineered bearings with larger diameters and monobloc metal cups) of MoM bearings (Fig. 1 (C), (D) & (G)). It originates from the necessity for a revision option after failure of the femoral component (e.g. femoral neck fracture) in hip resurfacing arthroplasty and was introduced together with the revival of resurfacing arthroplasty around 1995. The large-head MoM option was promoted for well fixed monobloc metal cups and allowed to revise the femoral side alone. Since the approval of resurfacing implants was delayed in some countries and the excitement for very large metal articulations was major, very large MoM implants opened a possibility to use very large metal articulations for primary surgery, since these heads were seen as a modification of the conventional systems of Categories 1 and 2a, which had proven good clinical success. Monobloc cups are always made from CoCr-alloys since this material is needed for the bearing surface (Fig 4). Category 2b designs are typically used in conjunction with a modular uncemented hip stem made from Ti-Alloy. The monobloc metal cups are implanted without cement.




Figure 4: Monobloc metal hip cup made from CoCr-alloy:
(A) Backside: Ingrowth surface
(B) Frontside: Bearing articulation. (Source: M.Morlock)

Category 2 Resurfacing

The revival of resurfacing arthroplasty – after the bad results with the Wagner resurfacing design in the 1970s and 1980s - was driven by Amstutz and McMinn around 1995. After several publications of good short and midterm results, resurfacing became popular very quickly and many companies introduced own designs into the market (Fig. 5). The resurfacing head of Category 2 designs made from CoCr-alloys is cemented onto a reamed femoral head in most designs, the monobloc cup made from CoCr-alloy is used without cement in all designs.



Figure 5: Examples for different designs of hip resurfacing implants. (Source: M.Morlock)

Appendix 2: Selected recommendations for the management of patients with implanted MoM hip arthroplasties from national health authorities and scientific organisations

Issued: 25 June 2012 at 11:00

Ref: MDA/2012/036

Appendix

Management recommendations for patients with metal-on-metal hip replacement implants

	MoM hip resurfacing (no stem)		Stemmed MoM total hip replacements – femoral head diameter <36mm		Stemmed MoM total hip replacements – femoral head diameter ≥36mm		DePuy ASR™ hip replacements (all types)	
	Symptomatic patients	Asymptomatic patients	Symptomatic patients	Asymptomatic patients	Symptomatic patients	Asymptomatic patients	Symptomatic Patients	Asymptomatic patients
Patient follow-up	Annually for the life of the implant	According to local protocols	Annually for the life of the implant	According to local protocols	Annually for the life of the implant	Annually for the life of the implant	Annually for the life of the implant	Annually for the life of the implant
Imaging: MARS MRI or ultrasound	Recommended in all cases	No - unless concern exists for cohort or patient becomes symptomatic	Recommended in all cases	No - unless concern exists for cohort or patient becomes symptomatic	Recommended in all cases	Recommended if blood metal ion levels rising	Recommended in all cases	Recommended in all cases
1st blood metal ion level test	Yes	No - unless concern exists for cohort or patient becomes symptomatic	Yes	No - unless concern exists for cohort or patient becomes symptomatic	Yes	Yes	Yes	Yes
Results of 1st blood metal ion level test	Blood metal ion level >7ppb indicates potential for soft tissue reaction		Blood metal ion level >7ppb indicates potential for soft tissue reaction		Blood metal ion level >7ppb indicates potential for soft tissue reaction	If blood metal ion level >7ppb then second blood test required 3 months later	Blood metal ion level >7ppb indicates potential for soft tissue reaction	If blood metal ion level >7ppb then second blood test required 3 months later
2nd blood metal ion level test	Yes - 3 months after 1 st blood test if result was >7ppb		Yes - 3 months after 1 st blood test if result was >7ppb		Yes - 3 months after 1 st blood test if result was >7ppb	Yes - 3 months after 1 st blood test if result was >7ppb	Yes - 3 months after 1 st blood test if result was >7ppb	Yes - 3 months after 1 st blood test if result was >7ppb
Results of 2nd blood metal ion level test	Blood metal ion level >7ppb indicates potential for soft tissue reaction especially if greater than previously		Blood metal ion level >7ppb indicates potential for soft tissue reaction especially if greater than previously		Blood metal ion level >7ppb indicates potential for soft tissue reaction especially if greater than previously	If blood metal ion levels rising - further investigation required including imaging	Blood metal ion level >7ppb indicates potential for soft tissue reaction especially if greater than previously	Blood metal ion level rising indicates potential for soft tissue reaction
Consider need for revision	If imaging is abnormal and/or blood metal ion levels rising		If imaging is abnormal and/or blood metal ion levels rising		If imaging is abnormal and/or blood metal ion levels rising	If imaging is abnormal and/or blood metal ion levels rising	If imaging is abnormal and/or blood metal ion levels rising	If imaging is abnormal and/or blood metal ion levels rising

Notes and guidance on next page

Medical device alert of the Medicines and Healthcare products Regulatory Agency on all Metal-on-Metal (MoM) hip replacements. MDA/2012/036 Issued: 25 June 2012

(www.mhra.gov.uk/Publications/Safetywarnings/MedicalDeviceAlerts/CON079157)

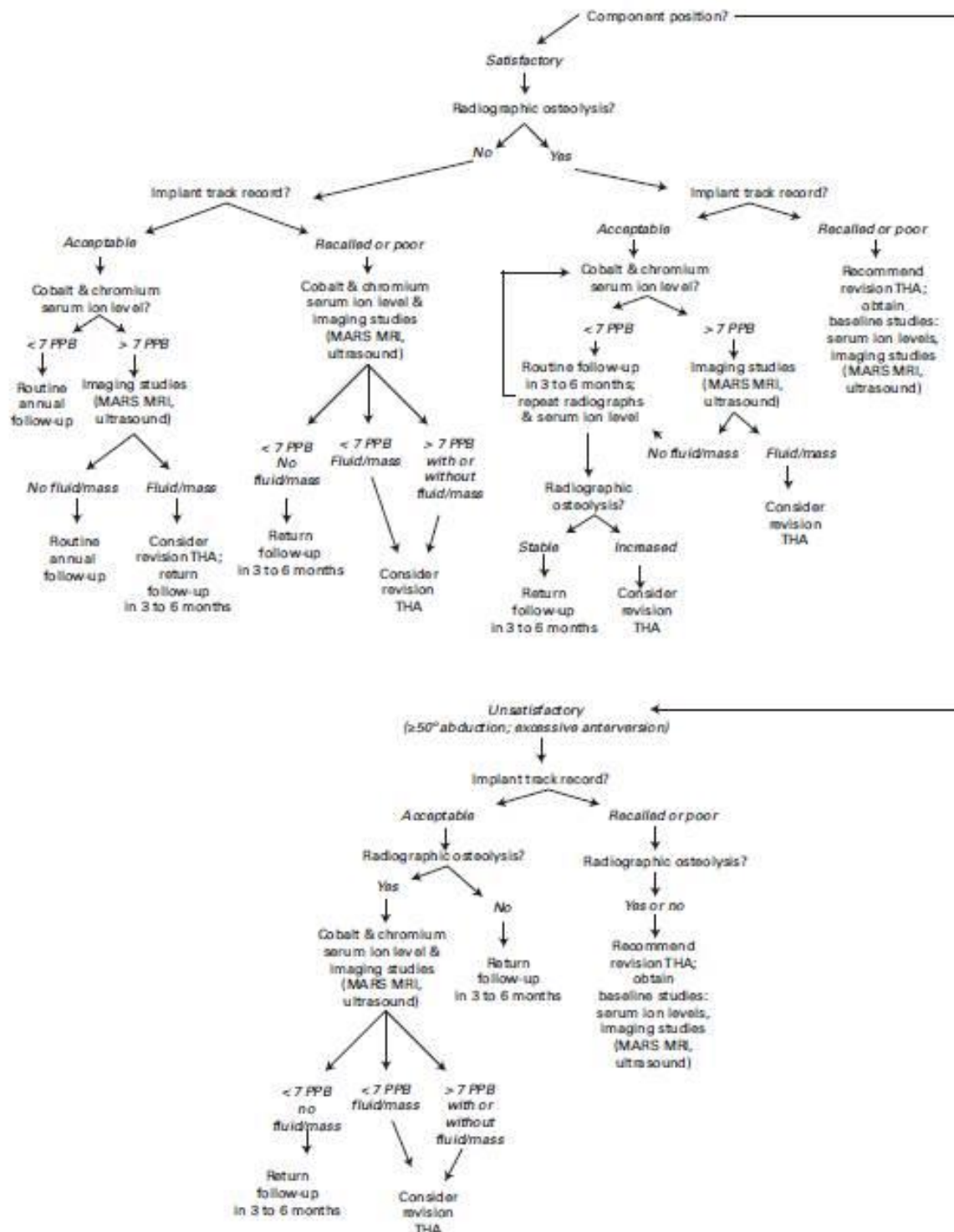


Fig. 1

An algorithm outlining the steps recommended for evaluating a patient who presents in follow-up after hip arthroplasty with an asymptomatic metal-on-metal articulation

Hip Society algorithmic approach to diagnosis and management of asymptomatic MoM hip arthroplasty patients (Lombardi et al 2012)

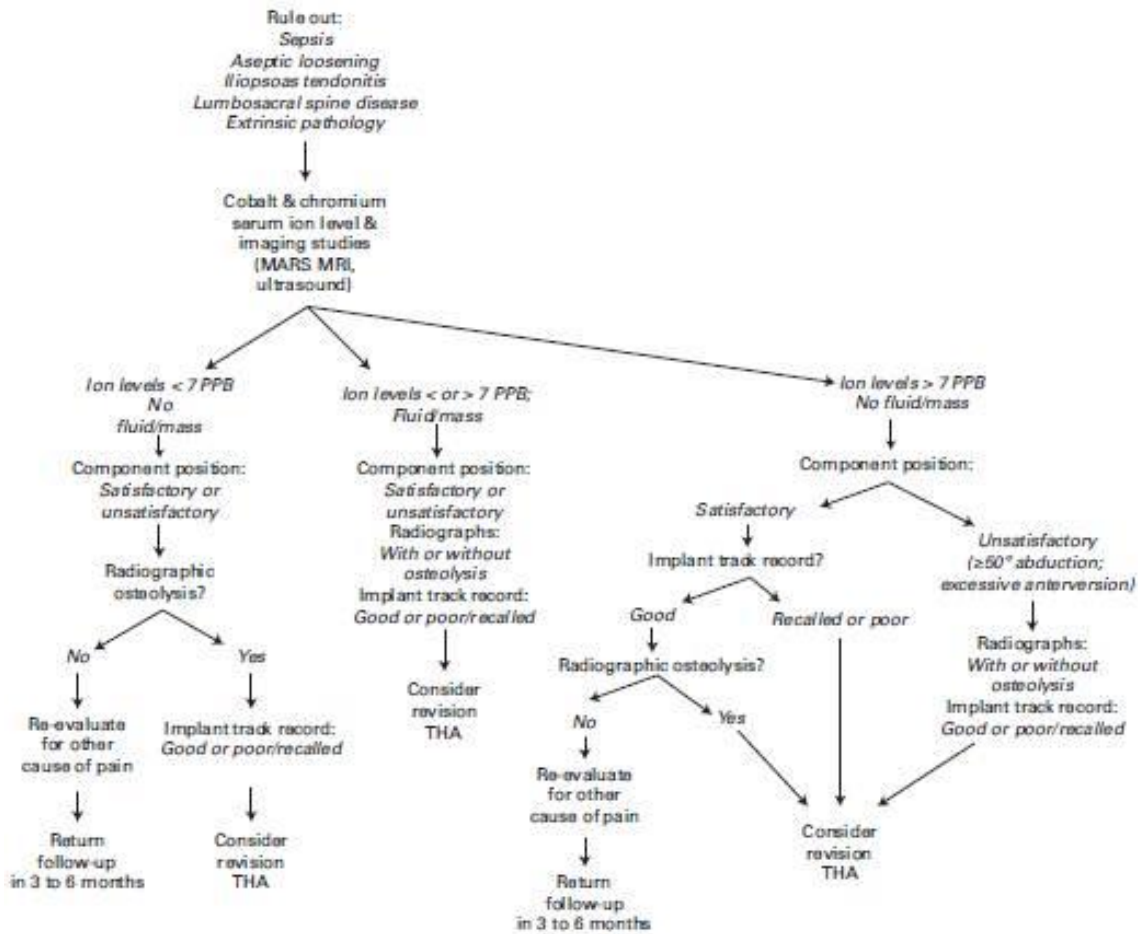


Fig. 2

An algorithm outlining the steps recommended for evaluating a patient who presents in follow-up after hip arthroplasty with a symptomatic metal-on-metal articulation

Hip Society algorithmic approach to diagnosis and management of symptomatic MoM hip arthroplasty patients (Lombardi et al 2012)